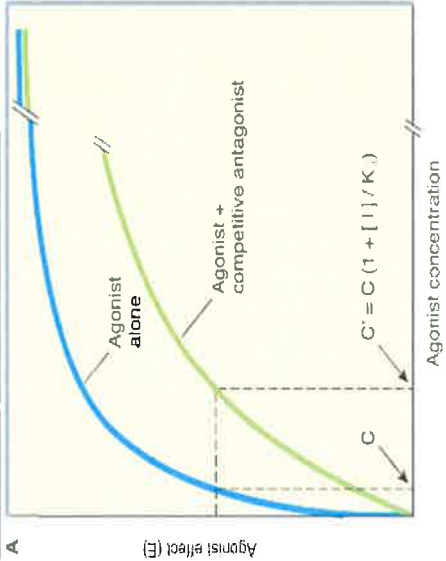


Stem: A 30 year old man has had a motor vehicle accident after a heroin overdose, and has been given Naloxone. Commencing with Pharmacology:

TOPIC	QUESTIONS	KNOWLEDGE	NOTES
<p>PHARMACOLOGY Question 1</p> <p>LOA: 1</p>	<ol style="list-style-type: none"> 1. What is an antagonist? 2. What is the difference between a competitive and non-competitive antagonist? <p>What type of antagonist is naloxone?</p> <ol style="list-style-type: none"> 3. What effect does a competitive antagonist have on the concentration-effect curve? 	<p>1. Receptor antagonists bind to receptors but do not activate them. The primary action of antagonists is to prevent agonists from activating receptors.</p> <p>2. Competitive antagonist: In the presence of increasing concentration of antagonist, higher concentrations of agonist will produce a given effect. Eg propranolol and noradrenaline / adrenaline. Irreversible or non competitive antagonist Bind via covalent bonds or just binding so tightly to receptor so receptor unavailable for agonist. Duration of action of antagonist depend on rate of turnover of receptor-antagonist molecules.</p> <p>Competitive</p> <p>3. Shift agonist vs effect curve to right. Higher concentrations of agonist can overcome competitive antagonist</p>	<p>Bold to pass</p>
			

Stem: Moving on to Anatomy: On examination, the patient is very tender over his pelvis.

<p>ANATOMY Question 2 LOA: 1</p>	<ol style="list-style-type: none"> 1. Demonstrate the major anatomical features of the pelvis. 2. What is this? (AIIS) What attaches here? What is this? (ASIS) What attaches here? 3. Describe the course of the iliac arteries. 	<p>Pubic symphysis, inferior and superior pubic rami, obturator foramen, acetabulum, iliac crest, sacro-iliac joint, sacrum.</p> <p>AIIS- Rectus femoris ASIS- Sartorius</p> <p>Common iliac origin from aorta L3-5 Follows medial border of Psoas to pelvic brim Divides at level of L5/S1 Internal iliac artery enters pelvis External iliac artery follows iliopectineus ends at the inguinal ligament and becomes femoral artery at mid-inguinal point</p>	<p>6 major features to pass</p> <p>3/4 to pass</p> <p>Bold to pass</p>
--	--	--	---

Stem: Moving on to Pathology: The patient becomes hypotensive.

PATHOLOGY
Question 3

LOA: 1

1. What is hypovolaemic shock?
2. Describe the stages of hypovolaemic shock
Prompt: What compensatory mechanisms are involved?

1. **Systemic hypoperfusion due to reduced effective circulating blood volume** resulting in **impaired tissue perfusion** and cellular hypoxia
2. **A. Non-Progressive phase** – reflex **compensatory mechanisms** activated to **maintain vital organ perfusion.**
Variety of neurohumoral mechanisms activated to help maintain cardiac output and blood pressure (baroreceptors and reflexes, release of catecholamines, activation of renin-angiotensin axis, ADH release and increased sympathetic output resulting in: tachycardia, peripheral vasoconstriction, and renal conservation of fluid with decreased urine output.

Coronary and cerebral vessels less sensitive to sympathetic response and blood flow/
O₂ delivery spared.
- B. Progressive phase- tissue hypoperfusion** and worsening circulatory and metabolic imbalance including **acidosis.**
Widespread tissue hypoxia resulting in anaerobic glycolysis with excess lactic acidosis production blunts vasomotor response → peripheral pooling, hypoxic injury, DIC, vital organs begin to failure
- C. Irreversible phase** - after body has incurred **cellular and tissue injury so severe** that even if haemodynamic defects are corrected, **survival is not possible**
 - Widespread cell injury
 - lysosomal enzyme release
 - nitric oxide → decreased myocardial contractility
 - acute tubular necrosis -> acute renal failure,
 - ischaemic gut → bacteraemic shock
 - severe hypotension, unconscious, anuric
 - pre-cardiac arrest - > death

Bold to pass

All 3 phases to pass.
2A.
Bold to pass + 3 features (prompt if necessary)

2B
Bold to pass.

2C
Bold to pass

3 features to pass

Stem: Moving on to Physiology: The patient complains of shoulder tip pain that is thought to be referred from his abdomen.

PHYSIOLOGY

Question 4

LOA: 2

1. Define the term "referred pain"
2. From which structure is pain referred to the shoulder?
3. Explain this relationship
4. Can you give another example of referred pain?
5. (EXTRA if good candidate) What is the physiological basis/theory for referred pain

1. Irritation of a visceral organ causing pain in a distant somatic structure
2. Diaphragm
3. Dermatome rule. Referred pain is usually to a structure that **developed from the same embryonic segment or dermatome** as the structure from which the pain originates
4. Cardiac pain to arm.
Ureteric pain to testicle.
5. Convergence-Projection Theory. Somatic and visceral pain fibres converge on the same second-order neurons in dorsal horn that then go on to thalamus and sensory cortex via common path. Sensory cortex cannot determine whether the stimulus came from viscera or are of referral

Bold to pass

Bold to pass

Bold to pass

1 to Pass

Stem: A 60 yr old woman presents with severe jaw pain following a dental extraction a month earlier and is given IV morphine. Commencing with Pharmacology:

TOPIC	QUESTIONS	KNOWLEDGE	NOTES
PHARMACOLOGY Question 1 LOA: 1	<ol style="list-style-type: none"> Define drug elimination half life Prompt: Is there a formula you can use? How does knowledge of a drug's half life help us clinically? What disease states can affect elimination half-life? What disease state could affect the elimination half-life of morphine? 	<p>Time required to change the amount of drug in the body by ½ during elimination</p> <p>$T_{1/2} = 0.7 \times V_d / \text{clearance}$ (0.7 approx log 2) 50% after 1, >90% after 4</p> <p>Dosing regimens Decay after dose/overdose Time to steady state after dose change</p> <p>Liver, renal, cardiac disease</p> <p>Liver, renal</p>	<p>Bold to pass</p> <p>2 to pass</p> <p>one organ</p> <p>one organ</p>

Stem: Moving on to Anatomy: You are planning to do a nerve block to relieve her pain.

ANATOMY Question 2 LOA: 2	<ol style="list-style-type: none"> Which Nerves run on or within the bony mandible Show the course of the inferior alveolar N on this mandible and why it is prone to injury? Why is it prone to injury? If the lingual N is damaged what deficits would you expect? 	<p>Inf alveolar/mental N (V3- mandibular) Lingual N ((V3+ chorda tympani) + 1 other of Auriculotemporal N (V3) N to mylohyoid (V3- branch of inf alveolar) Mandibular branch of the facial N (VII)</p> <p>Early large branch of mandibular trigeminal after it exits the Foramen ovale, runs on surface of inside mandible ramus to Mandibular foramen, (gives off N to mylohyoid), Passes inf and ant thru bone in alveolar canal which is v close to roots of 3rd molar supplying all lower teeth and exits as (mental N) from mental foramen ant/ superior (in edentulous)</p> <p>Close relationship to bony mandible Ant 2/3 tongue- taste + sensory loss (via the chorda tympani) Loss of secretory function –submandibular salivary glands Sensory loss to floor of mouth and/ or to gums</p>	<p>Bold to pass</p>
--	--	--	---------------------

Stem: Moving on to Pathology: Her Xray reveals evidence of bony destruction in the mandible.

PATHOLOGY

Question 3

LOA: 1

1. Describe the pathogenesis of osteomyelitis.
Prompt: How would this patient have suffered a bony infection of his jaw?
2. What organisms cause osteomyelitis?
3. What changes occur in the bone?
4. What are the clinical consequences of osteomyelitis?

Local infection related to extraction of tooth
Blood borne
Spread from neighbouring gingival source.

Staph Aureus majority >80% pyogenic
E Coli, KI Pneum, Pseudo A, from GU tract or IVDU
H Infl and GBS in neonates
Viruses, Fungi, Parasites, TB, syphilis also
About 50% no orgs found.

Acute inflammation and necrosis, abscess formation
Sclerosis and **involucrum** formation
Deformity and sequestrum formation, **Draining sinus**
Characteristic lytic focus surrounded by zone of necrosis on X ray, lifting of periosteum
5-25% become chronic inflammation

Resolution after Rx with IV antibiotics and drainage
Conversion to chronic O myelitis
Deformity and bony destruction
Severe sepsis syndrome, ARF etc.

2/3

Staph A and 1 other

Bold

2 to pass

Stem: Moving on to Physiology:

PHYSIOLOGY

Question 4

LOA: 1

1. What percentage of cardiac output goes to the kidneys?

2. How is renal blood flow regulated?

Prompts: What other mechanisms are there?

3. How can renal blood flow be measured?

4. Describe the differences in regional blood flow within the kidney.

RBF = 1.2-1.3L/min or approx 25% CO (adult)

Substances/Chemicals

Norepinephrine (noradrenaline)

- Constricts renal vessels
- Stimulates renal nerves to ↑ rennin secretion

Dopamine – renal v/dilatation

A II – arteriolar constrictor

PG - ↑cortex flow, ↓medulla flow

Ach – v/dilatation

High protein - ↑ b/flow

Renal Nerves

- Stimulation nerves = ↑ renin secretion, ↑IG sensitivity, ↑Na resorption, and renal vasoconstriction
- Strong stimulation sympathetic (noradr) ↓flow
- Fall in BP = v/constrict

Autoregulation

- Renal vasc resistance varies with pressure to keep RBF fairly constant
- Present in denervated kidney, but not if drugs that paralyse vasc sm muscle
- Factors = direct contractile response, NO, A II

- Fick principle – subs taken up/unit time
- PAH used to measure renal plasma flow
- Renal b/flow using plasma flow and Hct

- AV o2 difference for kidney = 14ml

- Cortical b/flow = 5ml/g/min

- Little o2 consumption

- Medulla b/flow low (outer = 2.5ml, inner= 0.6ml)

- Maintenance of osmotic gradient

RBF

3/6 substances plus nerve or auto – with example

One example

One aspect of regional blood flow to pass