

Advanced suturing tips

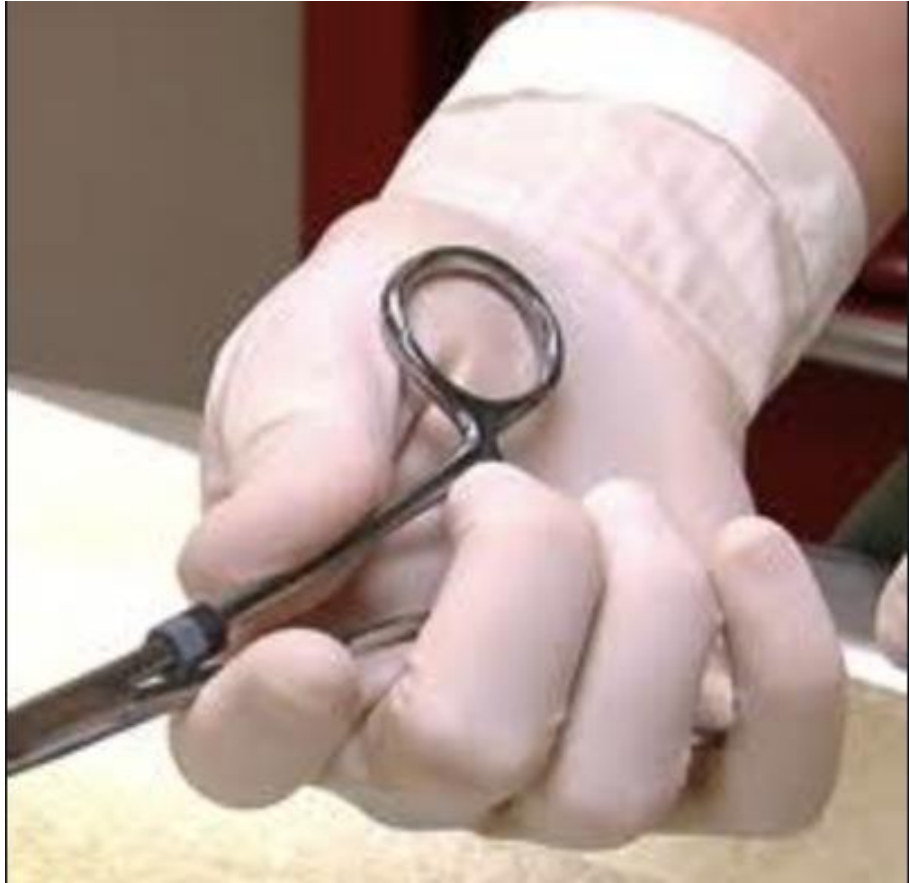Overview

- **Basics**
 - Square knots
 - Mattress sutures
 - Subcuticular
- **Techniques on wound eversion**
 - Mattress
 - Tie parallel to incision
- **Techniques on difficult lacerations/ incisions**
- **Techniques on dealing with wounds under tension**

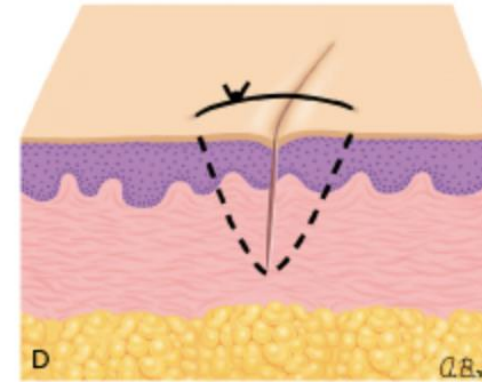
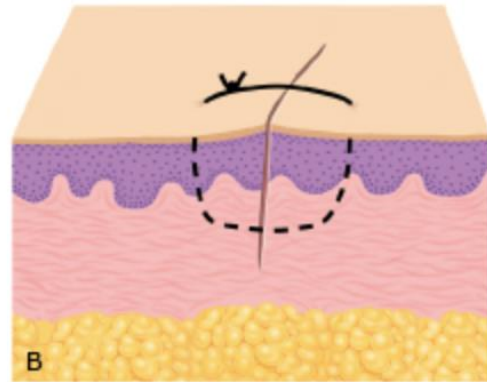
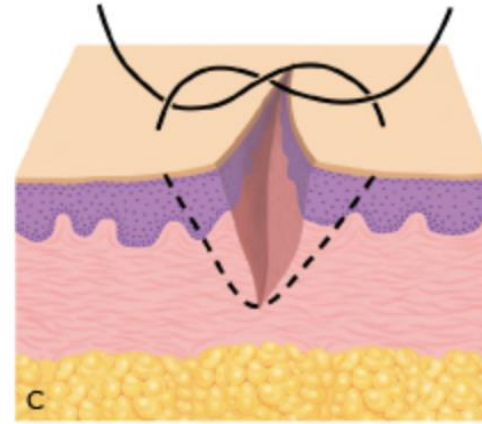
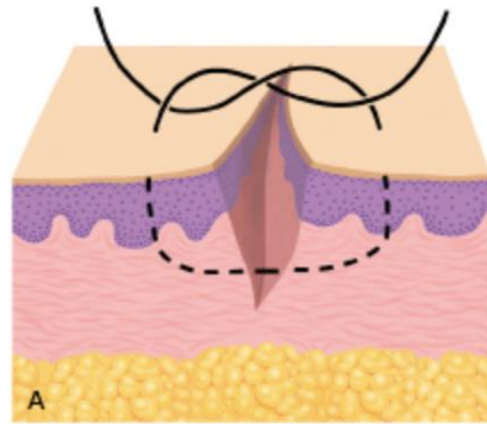
Basics

- Square knots
- Mattress sutures
- Subcuticular

Holding instruments



Wound eversion

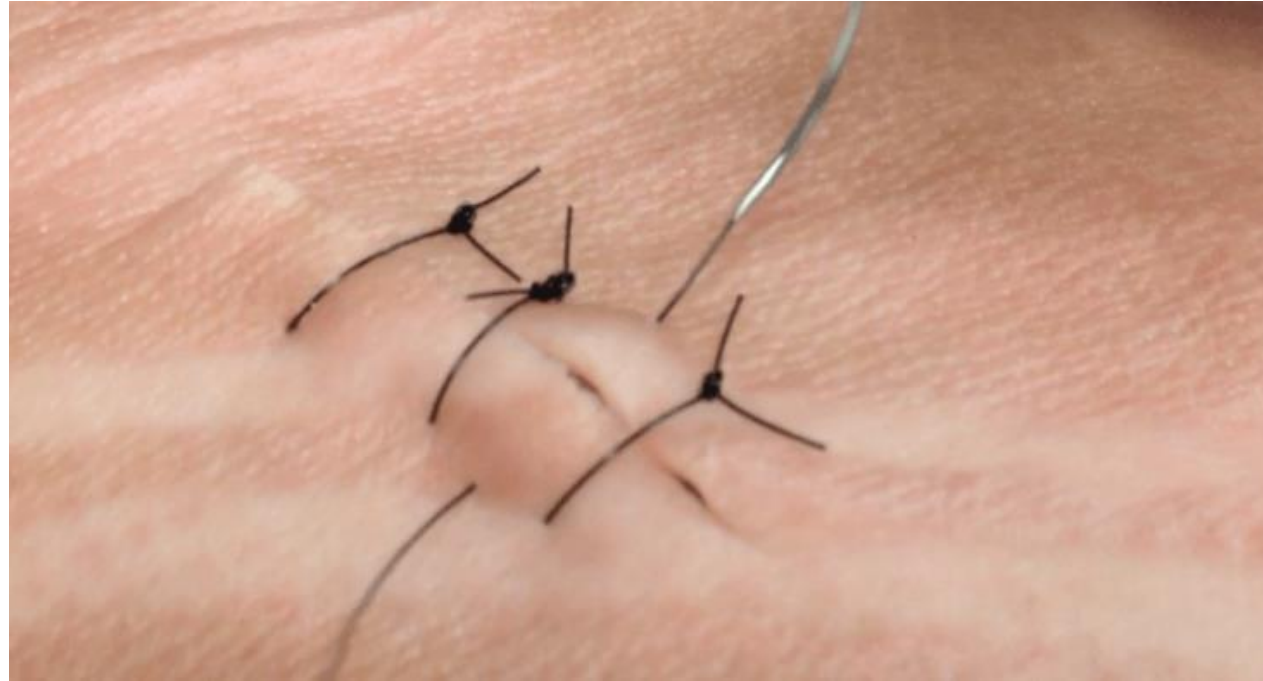


Proper technique

Improper technique

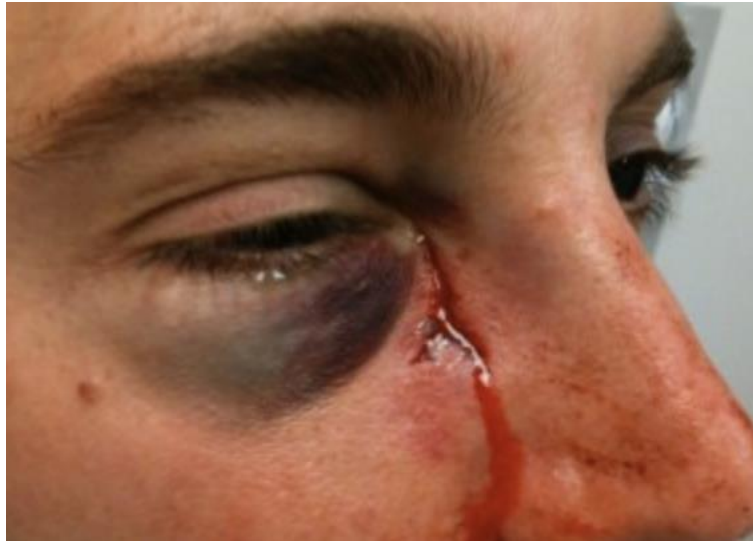Q.B.21

Tie knot parallel to incision



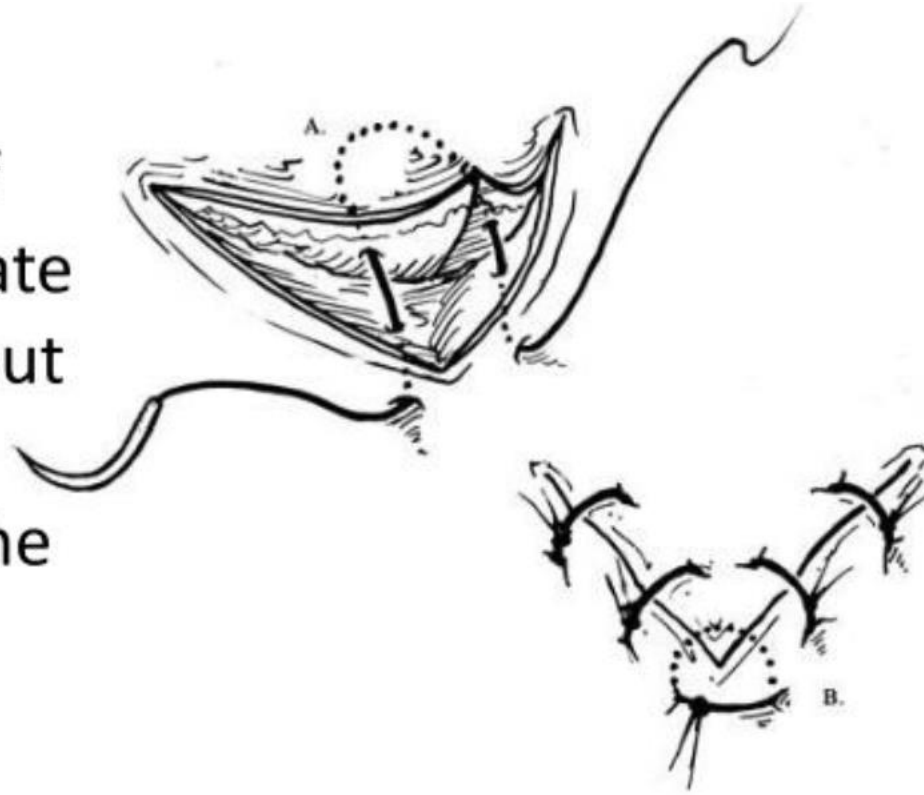
Difficult lacerations and incisions....

Stellate / flap lacerations

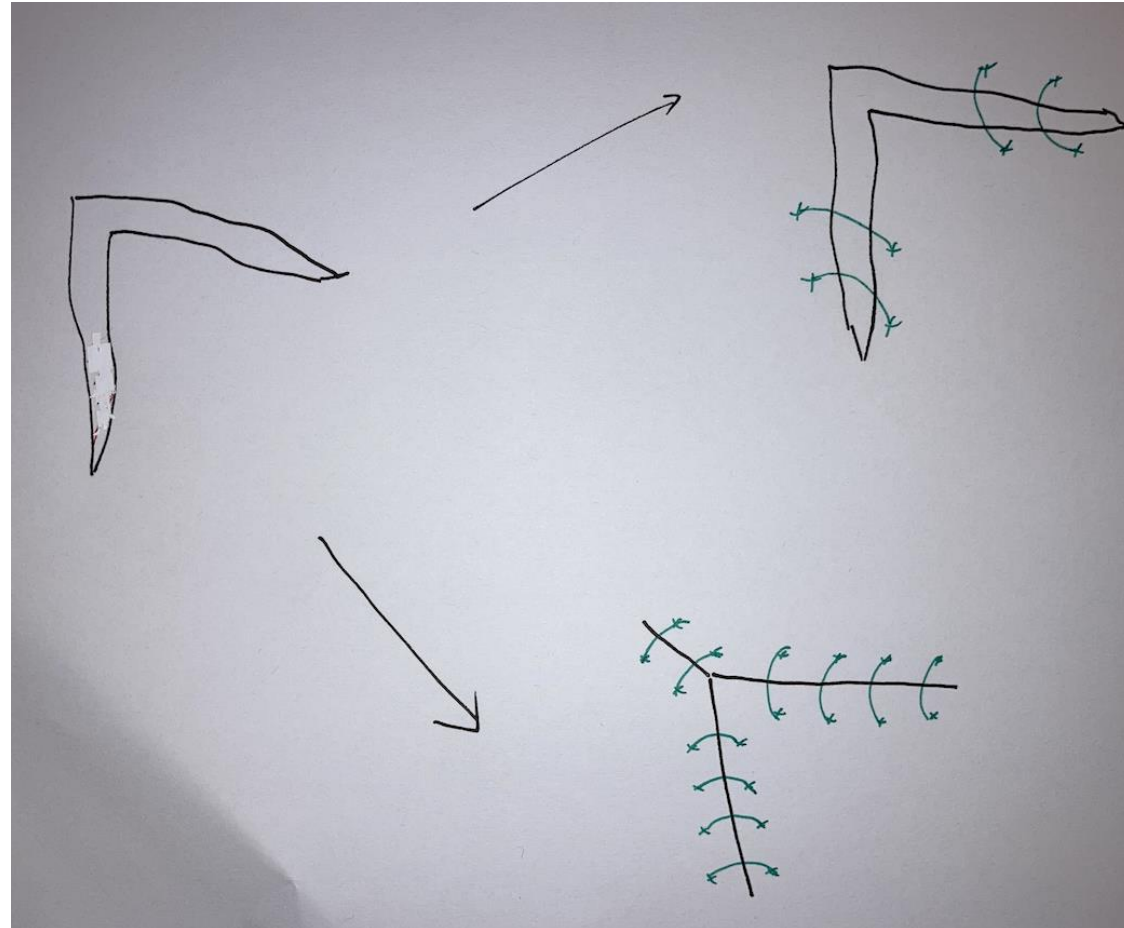


Corner stitch

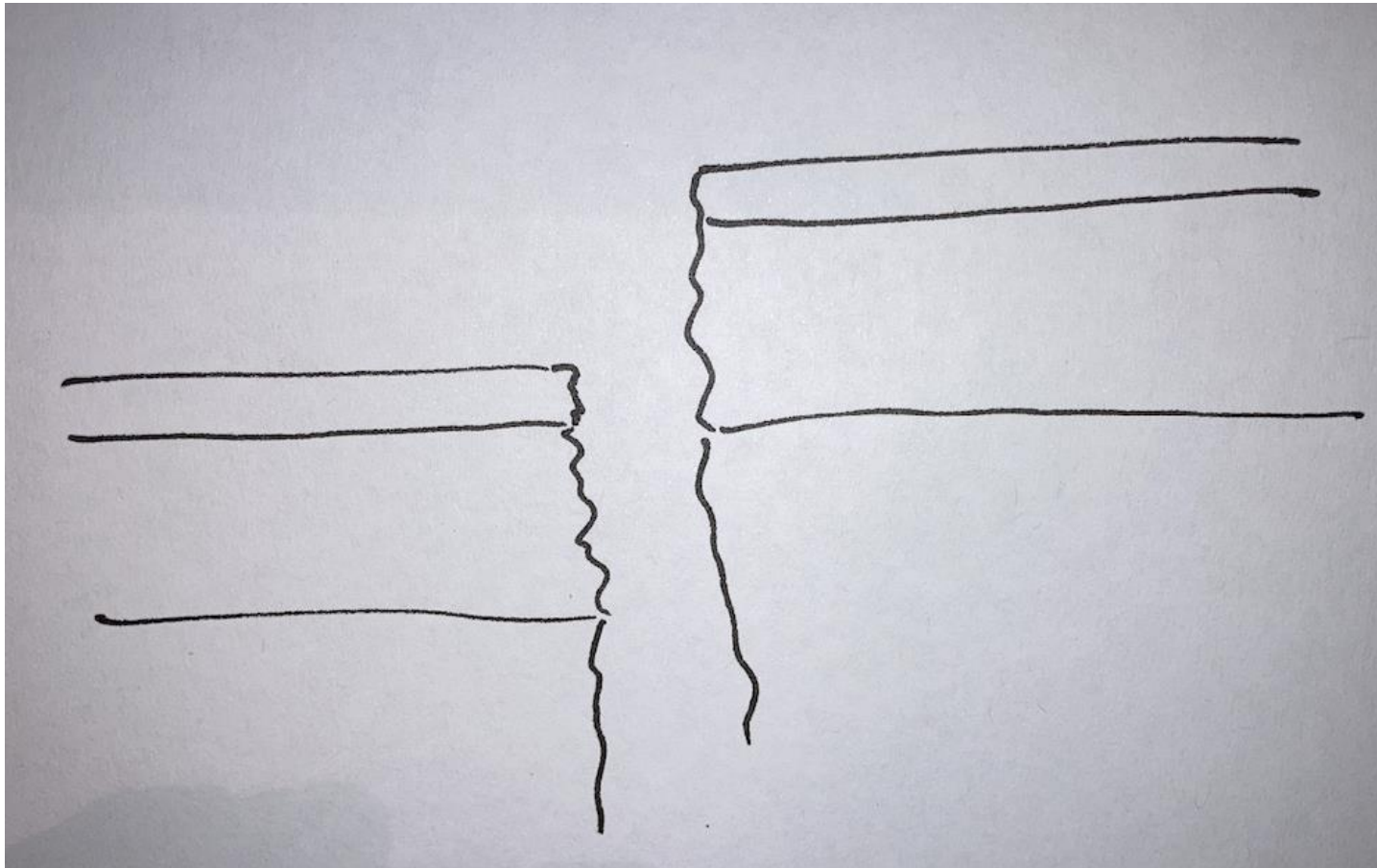
- Advantages:
approximation of
corners and stellate
lacerations without
capillary
compromise of the
corner



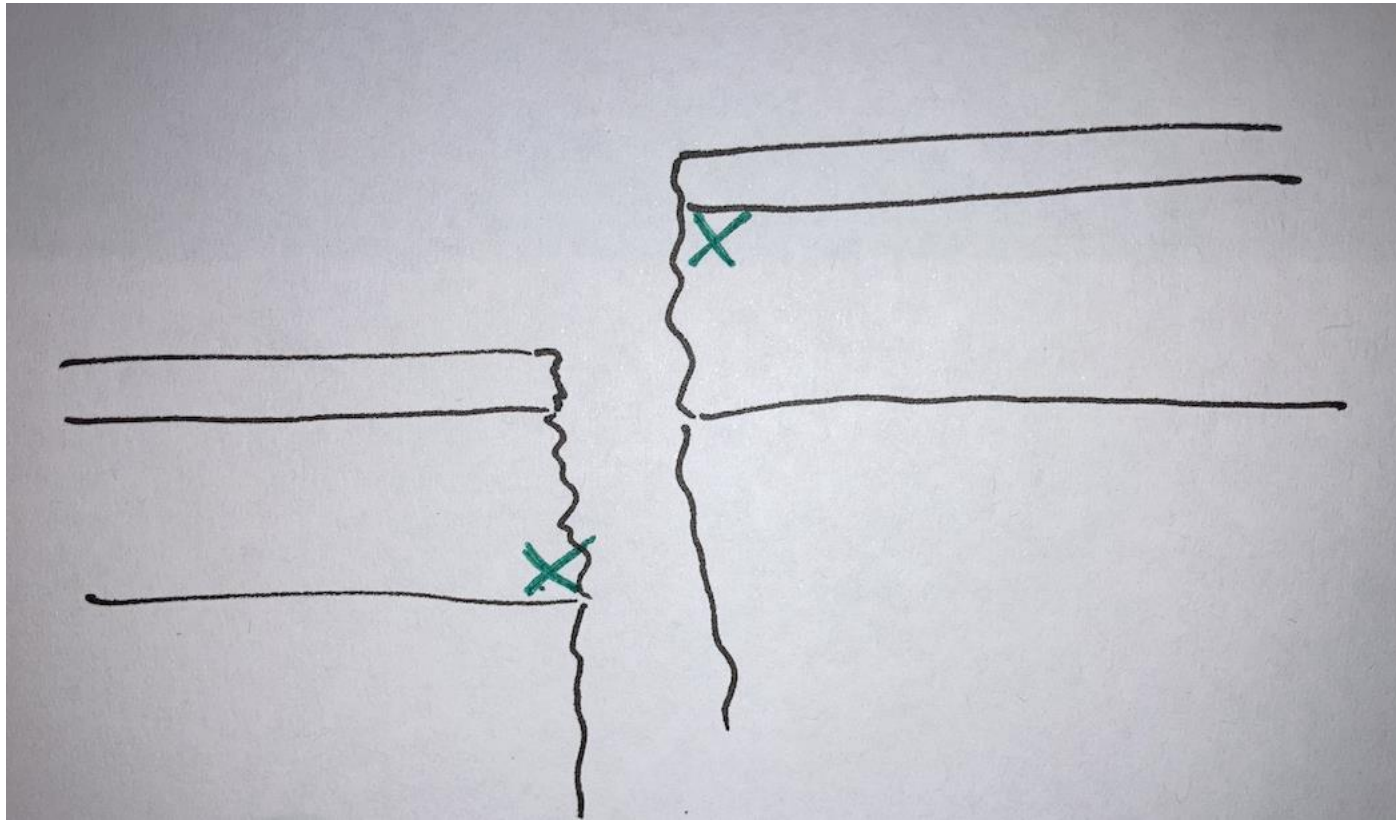
Flap lacerations



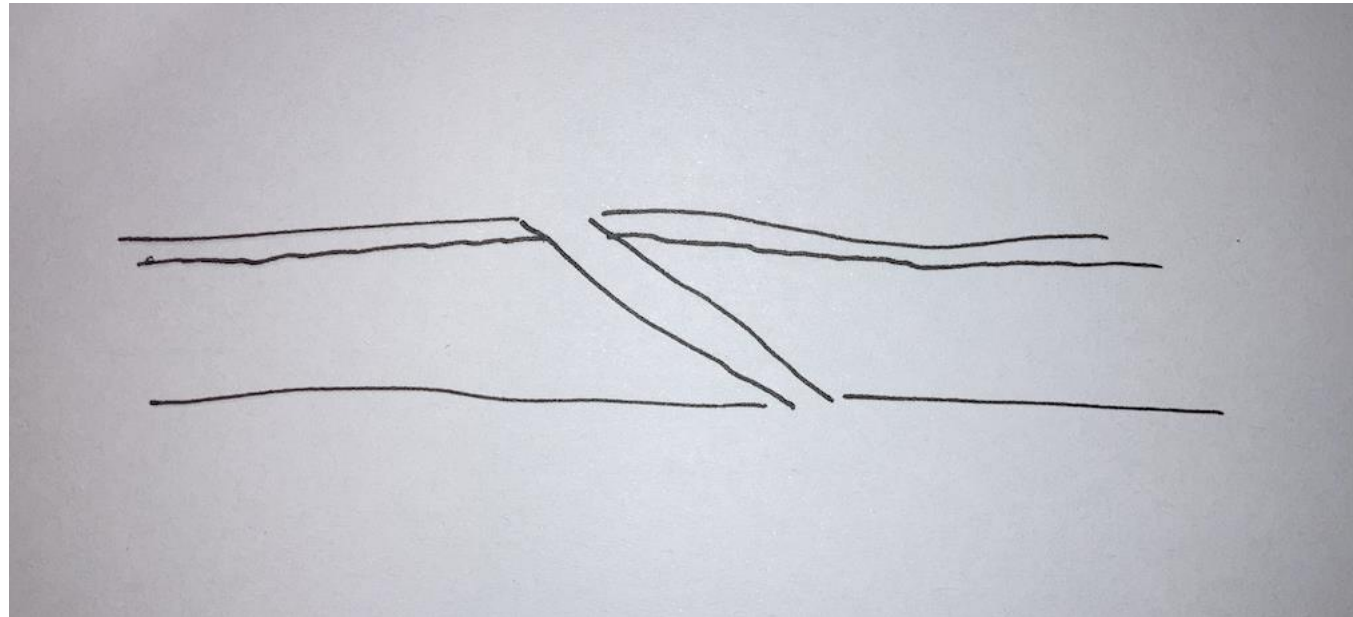
Differential in height

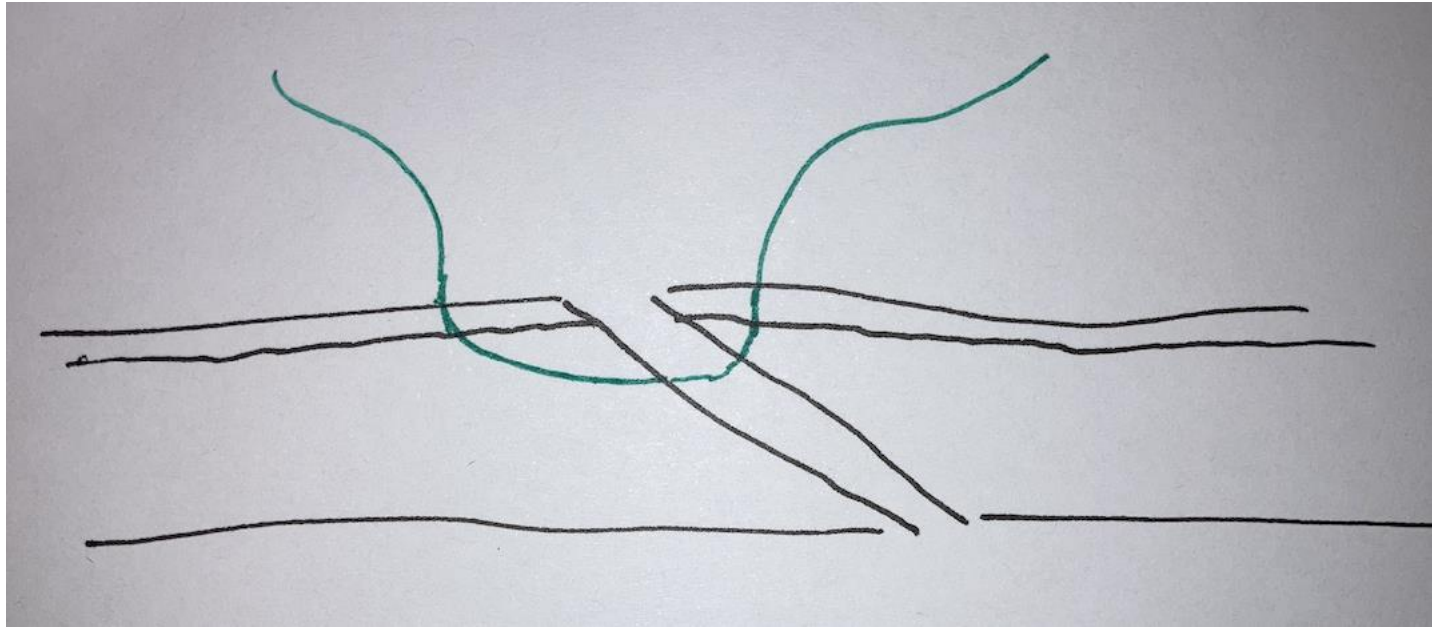


Differential in height

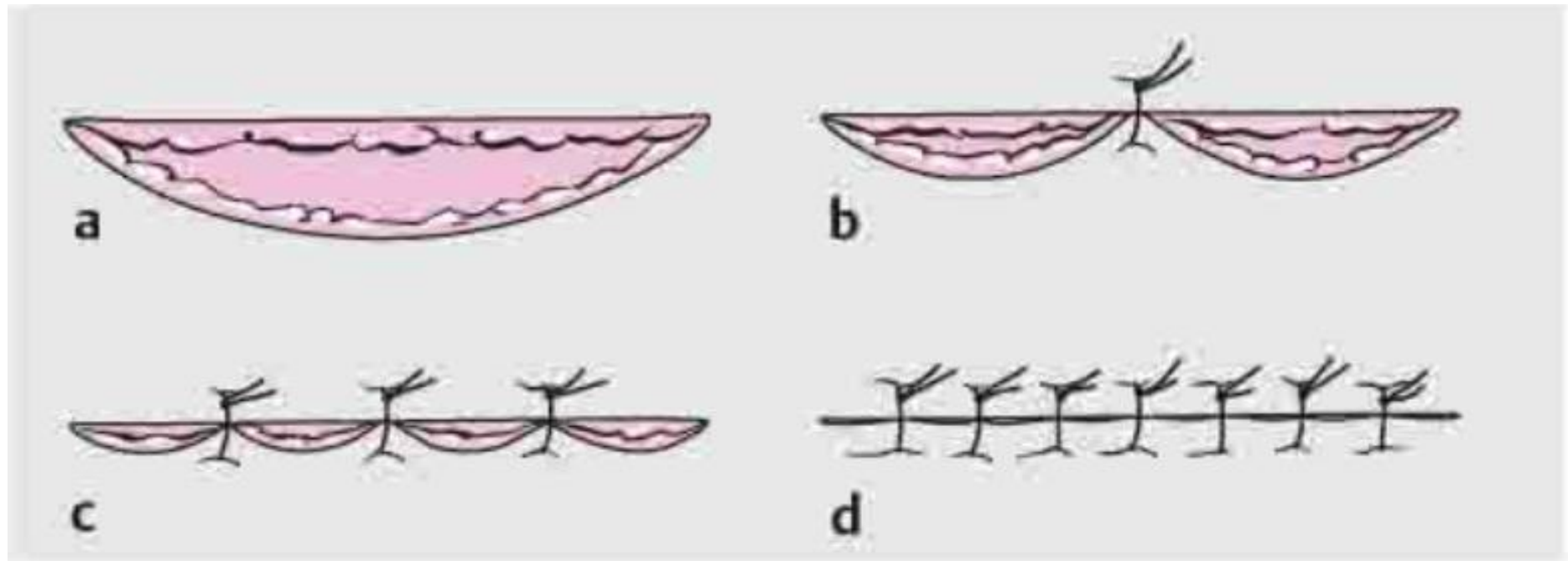


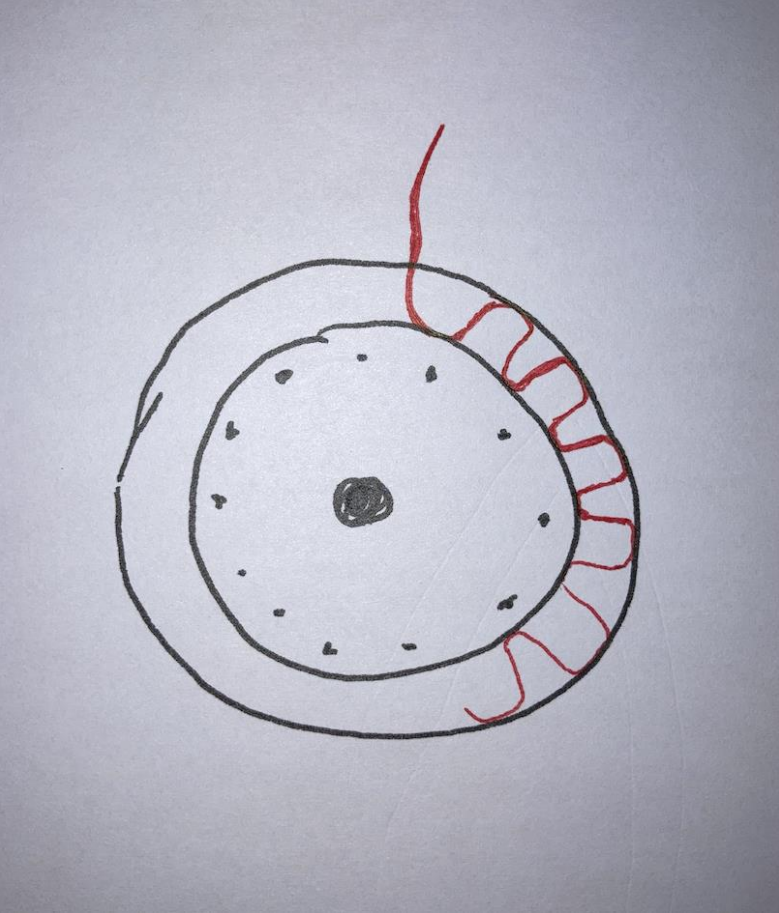
Shelving lacerations





Discrepancy in wound edge length





Wounds under tension (how to assist in closure)

- Instruments
- Assistant pinch
- Knot technique – hand tie or instrument tie sliding knot, self pinch