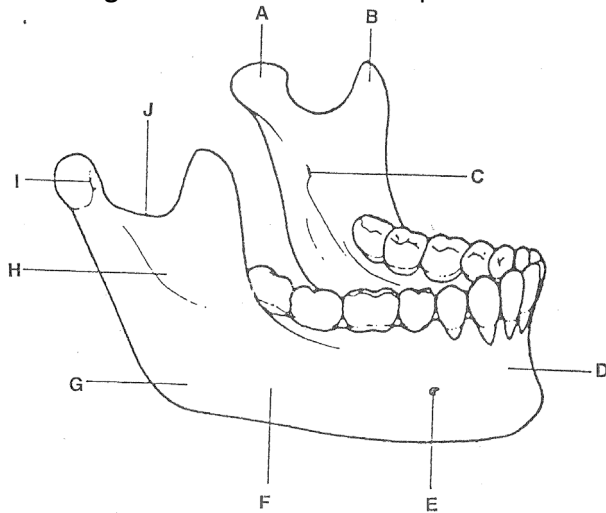


INFRATEMPORAL & TEMPORAL FOSSAE:

- **Mandible** (lower jaw) has 2 **mandibular condyles**
- Mandibular condyles articulate with the left and right **temporal bones** at the **temporomandibular joints (TMJ)**
- **Body** of the mandible lies on either side of the mouth and is continuous with the **mandibular symphysis** in the midline anteriorly.
- **Ascending ramus** runs between the posterior aspect of the body and the condyle above
- **Angle of the mandible** is the point where the body runs into the ascending ramus.

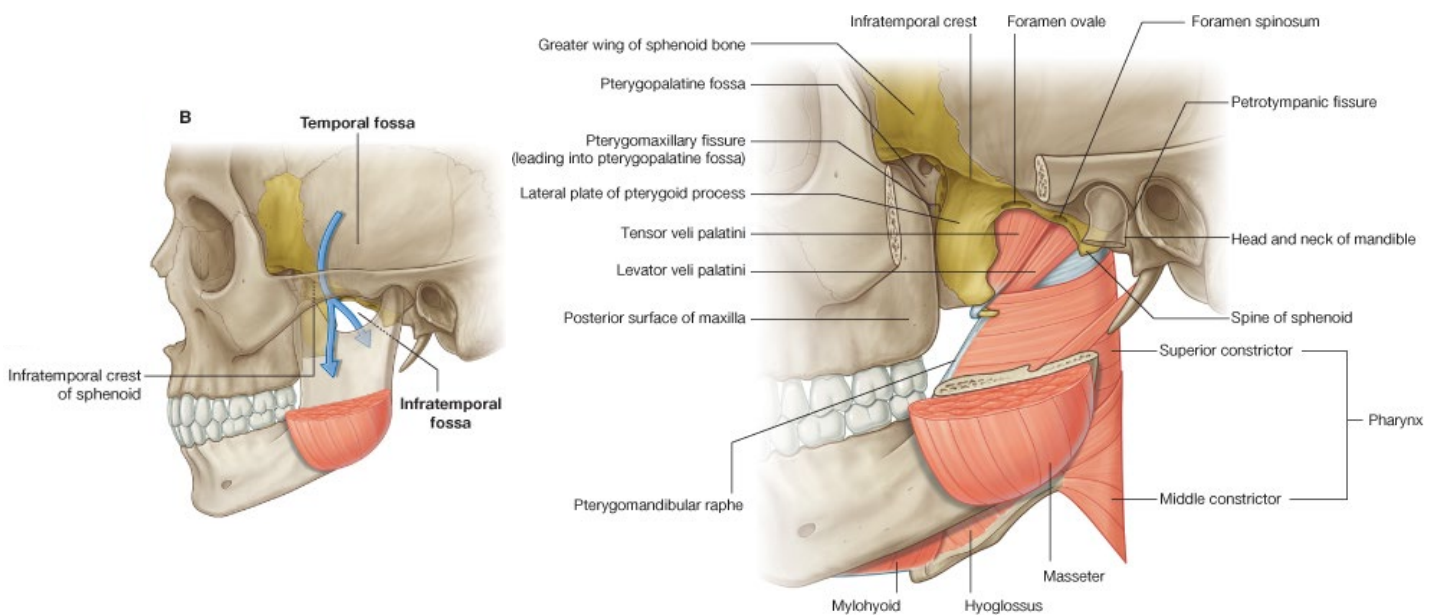


The mandible and its major bony landmarks.

A	Condyle	F	Body of mandible
B	Coronoid process	G	Angle of mandible
C	Mandibular foramen	H	Ascending ramus
D	Mandibular symphysis	I	Fovea
E	Mental foramen	J	Mandibular notch

○ Infratemporal fossa:

- Lies between the **pharynx** and the **ascending ramus** of the mandible
- Roof is formed by the base of the skull – esp. **undersurface of greater wing of sphenoid**
- Tympanic plate and styloid process of temporal bone lie at **back** of roof of infratemporal fossa.
- **Pterygoid plates** of sphenoid lie in **front**.

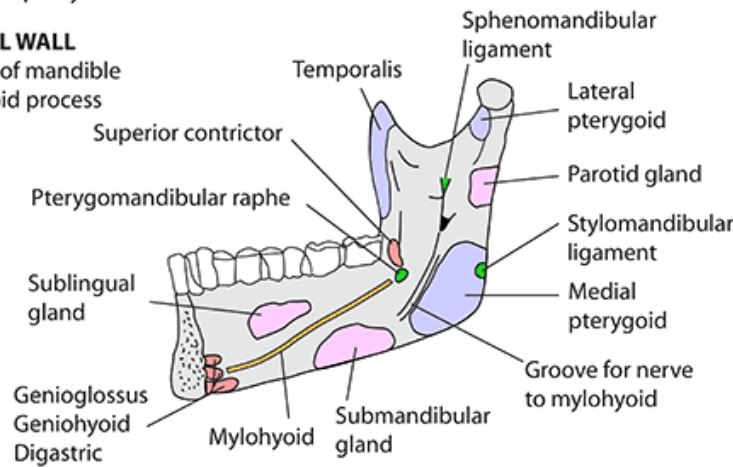


INFRATEMPORAL FOSSA - BOUNDARIES

- Base of skull
- Between pharynx & ramus of mandible

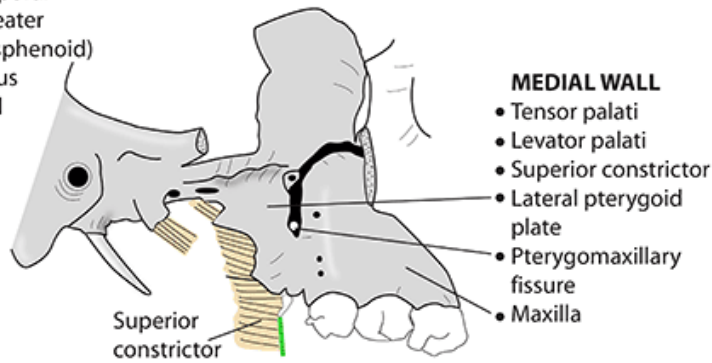
LATERAL WALL

- Ramus of mandible
- Coronoid process



ROOF

- Infratemporal crest (greater wing of sphenoid)
- Squamous temporal



MEDIAL WALL

- Tensor palati
- Levator palati
- Superior constrictor
- Lateral pterygoid plate
- Pterygomaxillary fissure
- Maxilla

POSTERIOR WALL

- Carotid sheath

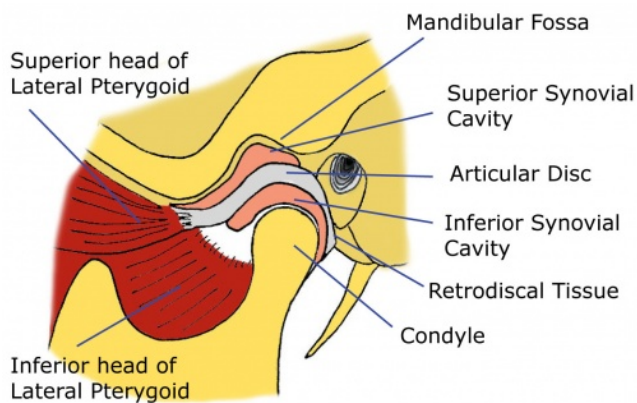
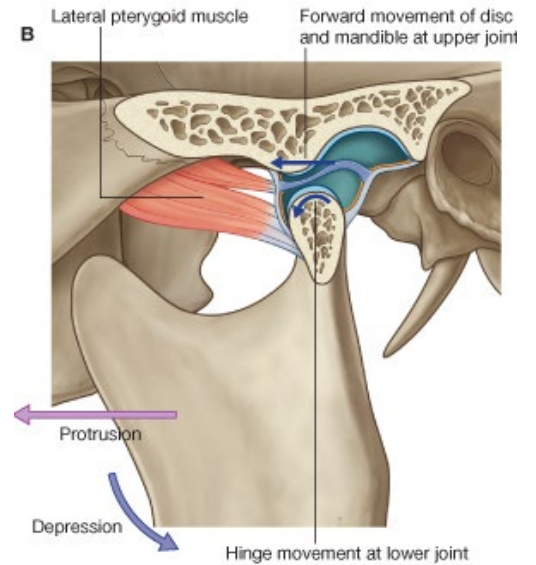
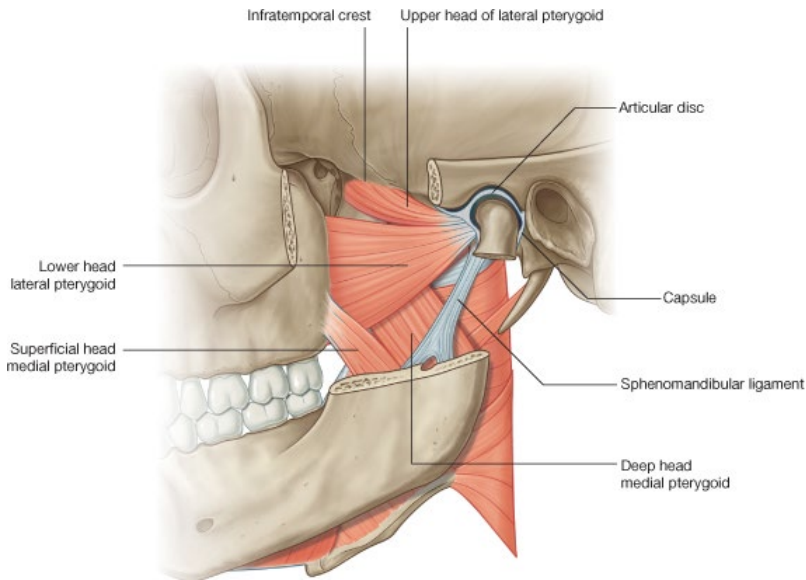
ANTERIOR WALL

- Posterior maxilla
- Inferior orbital fissure

MUSCLES OF MASTICATION:

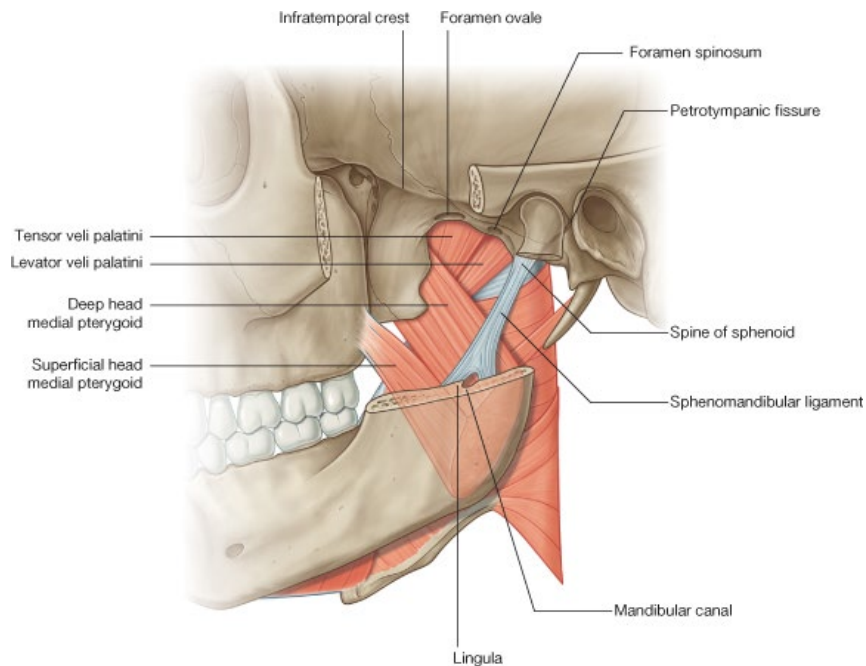
- **4** large muscles attached to the ascending ramus and condyle of the mandible
- Move the mandible during chewing, speaking and swallowing
- 2 muscles attach to the inside of the mandible:
 - **Medial pterygoid muscle (deep + superficial)**
 - **Lateral pterygoid muscle (upper + lower)**
- 2 muscles attach to the outside of the mandible:
 - **Masseter**
 - **Temporalis**
- **Lateral pterygoid:**
 - Arises as 2 heads from the **sphenoid**:
 - Undersurface of great wing of sphenoid (roof of fossa)
 - **Lateral** aspect of the **lateral pterygoid plate** of sphenoid (medial wall of fossa)
 - Insert into the:
 - **Fovea** of the neck of mandible (just below the condyles)
 - **Disc/meniscus** of the temporomandibular joint.

- Action is to:
 - Protrude chin
 - Open mouth
 - Close mouth (upper head fibres)
 - Stabilises the meniscus of the joint.



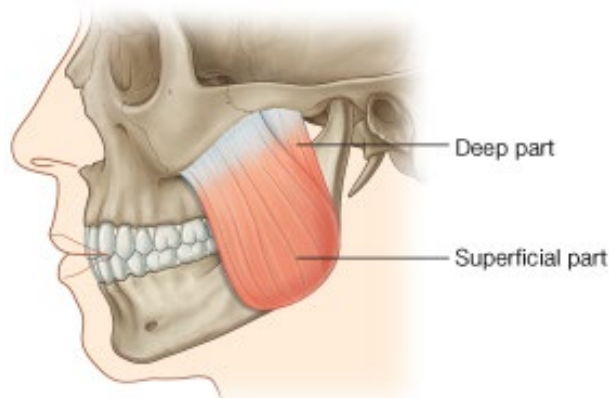
The Temporomandibular Joint

- **Medial pterygoid muscle:**
 - Arises from:
 - **Medial** aspect of **lateral pterygoid plate**
 - **Maxilla**
 - Inserts into inner aspect of the angle of the mandible
 - Active when closing jaw – e.g. biting.



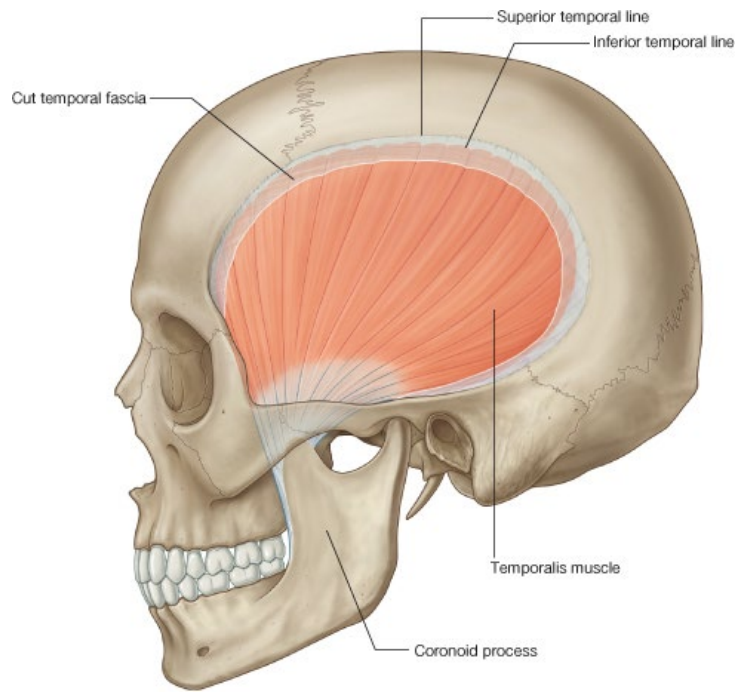
○ **Masseter muscle:**

- Arises from zygomatic arch
- Arises as 2 heads:
 - Deep head: inner surface of zygomatic arch
 - Superficial head: anterior undersurface of zygomatic arch
- Run downwards to insert into the ascending ramus of the mandible
- Action is to close the mandible and occlude the teeth.



○ **Temporalis muscle:**

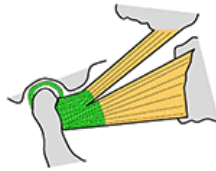
- Arises from side of vault of skull from tough fascia covering the bone – **temporalis fascia**
- Temporalis fascia covers the muscle.
- Side of the vault bones are marked with **temporal lines**, where the temporalis muscle takes origin.
- Temporalis muscle passes through **temporal fossa**
- Temporal fossa is bounded laterally by zygomatic arch.
- Temporalis inserts into:
 - **Coronoid process** of the mandible
 - **Inner aspect of ascending ramus**
- Closes jaw and occludes the teeth.



MUSCLES OF MASTICATION

- Temporalis
- Masseter
- Medial pterygoid
- Lateral pterygoid

- All supplied by:
- Mandibular division of Trigeminal (Vc)
 - All derived from 1st pharyngeal arch



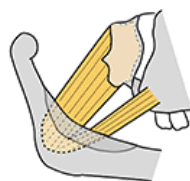
LATERAL PTERYGOID

Arises: 2 heads

Upper: infratemporal surface sphenoid
Lower: lateral surface of lateral pterygoid plate

Inserts: pterygoid fossa below head of mandible, disc, and capsule of temporomandibular joint

Action: protrudes jaw and opens mouth



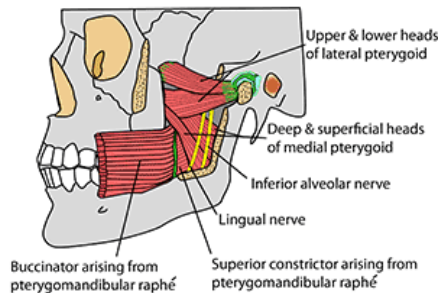
MEDIAL PTERYGOID

Arises: 2 heads

Deep: medial side of lateral pterygoid plate and fossa between plates
Superficial: smaller. Tuberosity of maxilla and pyramidal process of palatine bone

Inserts: Medial ramus of mandible

Action: pulls mandible upwards, forwards and medially (closes mouth and chews)



Pterygoid muscles contain venous plexuses that connect with veins both inside (cavernous sinus) and outside the skull (facial veins)

Chewing:

- Chewing is a complicated motion
- Muscles of mastication are active at different points in the cycle.
- Pterygoids and masseter play important role in lateral movement of the mandible to allow grinding of teeth.

Talking:

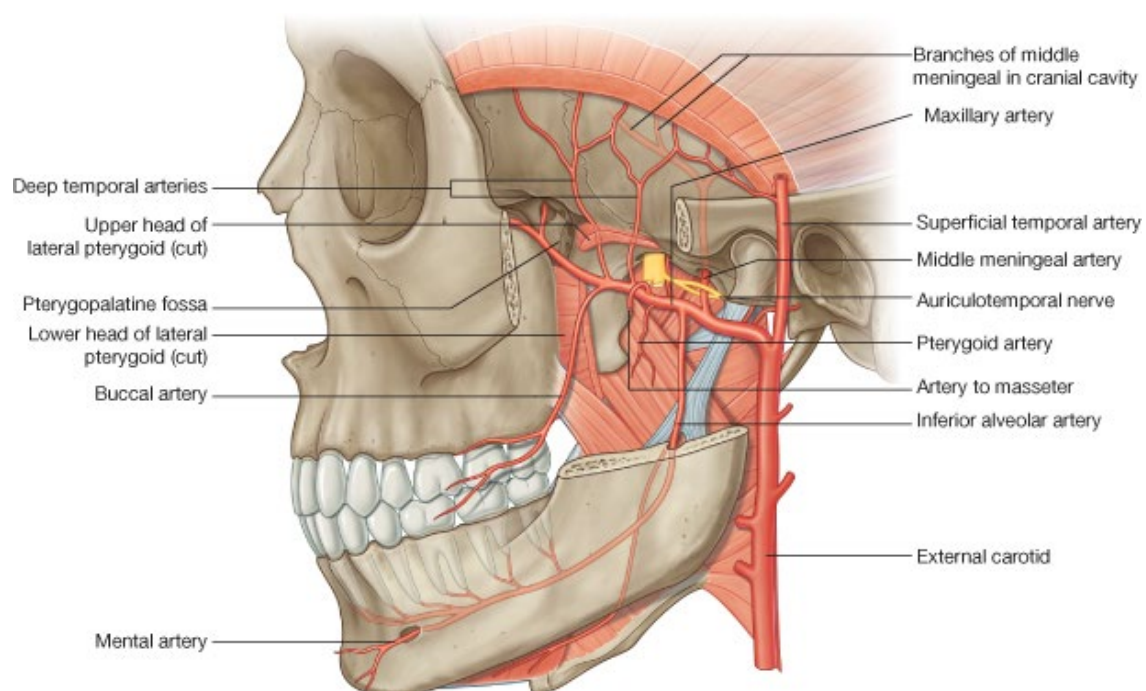
- Movement is only ever up and down (no lateral movement)

Swallowing:

- Always bilateral occlusion of jaw whilst tongue forces food backwards into oropharynx.

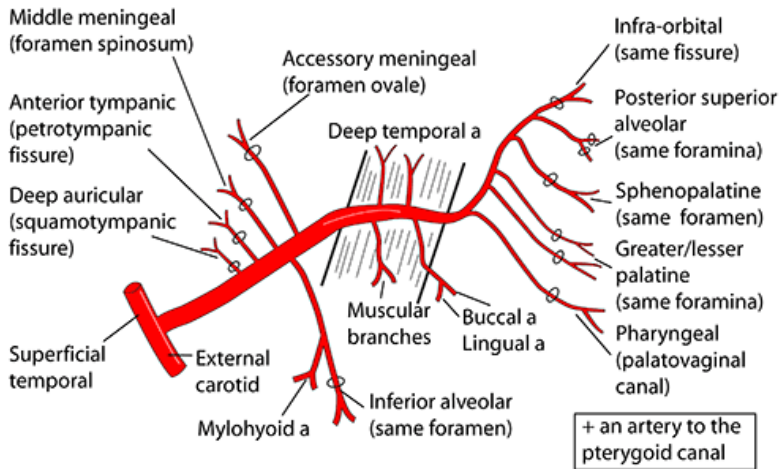
NERVES TO INFRATEMPORAL FOSSA:

- 2 nerves pass through skull base → infratemporal fossa
 - **Mandibular division (V_{iii})** – foramen ovale
 - **Facial nerve (VII)** – stylomastoid foramen
- **Mandibular nerve:**
 - Leaves through foramen ovale
 - Carries both *motor* and *senory* innervation to:
 - Infratemporal fossa
 - Mouth
- **Facial nerve (VII):**
 - Leaves skull through stylomastoid foramen
 - Supplies **motor** to superficial muscles of the face.
- Other structures passing through the back of the infratemporal fossa include:
 - Internal carotid artery
 - Internal jugular vein
 - Cranial nerves IX, X, XI & XII
- **Maxillary artery** is a terminal branch of the **external carotid**
- Runs a complicated course through the infratemporal fossa
- Accompanies branches of V₂ beyond the lateral pterygoid (in pterygopalatine fossa)
- **Parotid gland** is large salivary gland
- Lies behind ascending ramus of mandible
- Extends medially into infratemporal fossa
- (developmentally, the parotid gland migrates back from mouth → behind mandible)



MAXILLARY ARTERY

In infratemporal fossa, either within or lateral to the superficial head of lateral pterygoid muscle. This muscle is shown below

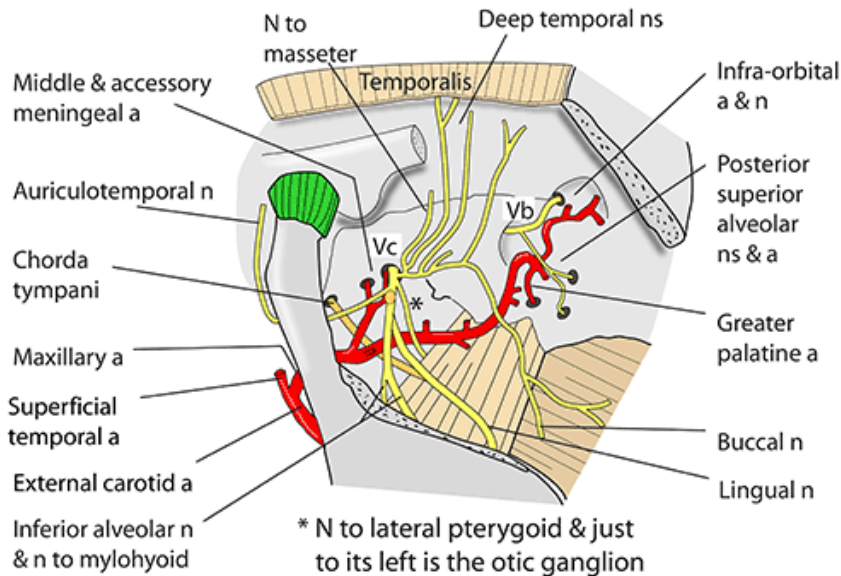


BEFORE LATERAL PTERYGOID
5 BRANCHES INTO BONE

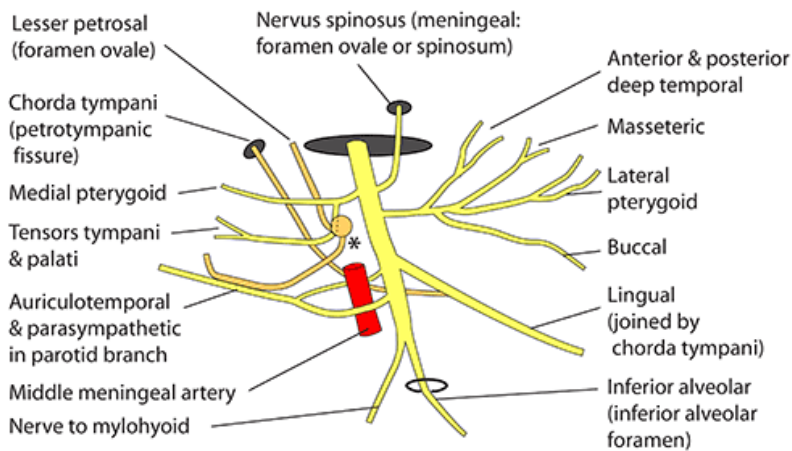
LATERAL OR WITHIN LATERAL PTERYGOID. 4/5 BRANCHES TO SOFT TISSUE

BEYOND LATERAL PTERYGOID
5/6 BRANCHES WITH NERVES

INFRATEMPORAL FOSSA - DEEP DISSECTION



MANDIBULAR DIVISION OF TRIGEMINAL NERVE (V_c), EMERGING FROM FORAMEN OVALE DEEP IN INFRATEMPORAL FOSSA



* Otic ganglion. Parasympathetics from lesser petrosal nerve synapse within it and post-ganglionic fibres are taken to the parotid gland by the auriculotemporal nerve

MANDIBULAR DIVISION (V_{iii}):

- Drops vertically through the foramen ovale in the base of the skull
- Unlike the other 2 divisions of trigeminal nerve (which are purely sensory), the mandibular division is both motor and sensory.
- In the infratemporal fossa, the mandibular division is:
 - Deep to lateral pterygoid
 - Superficial to tensor palati muscle.
- Gives off small **meningeal nerve** which travels through foramen spinosum with middle meningeal artery
- Sensory to:
 - Middle cranial fossa
 - Mastoid air cells
- **Otic ganglion** is a parasympathetic ganglion from mandibular branch, just below the foramen ovale.
- Contains synapses between preganglionic and postganglionic parasympathetic nerves to parotid gland.
- Also has sympathetic fibres running through it which don't synapse.
- Mandibular nerve divides into **anterior and posterior divisions**

Anterior division – motor:

- All the nerves of the anterior division are motor to muscles of:
 - Soft palate
 - Mastication:
 - Medial & lateral pterygoids

- Maseter muscles
 - Temporalis
- Tensor palati muscle
- Branch of anterior division which supplies maseter, travels through notch between the condyloid and coronoid process of mandible.
- **Long buccal nerve** is the only **sensory** nerve from the anterior division.
 - Supplies sensation to inside and outside of the cheek
 - Runs between the 2 heads of the lateral pterygoid.

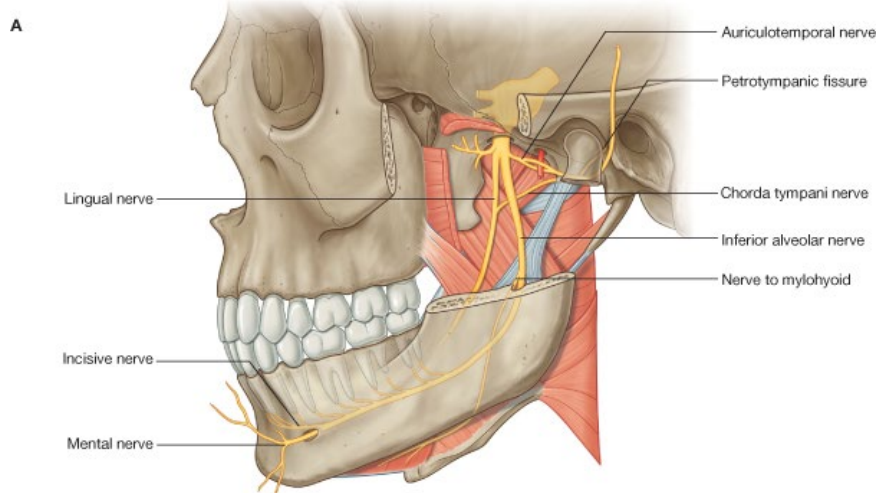
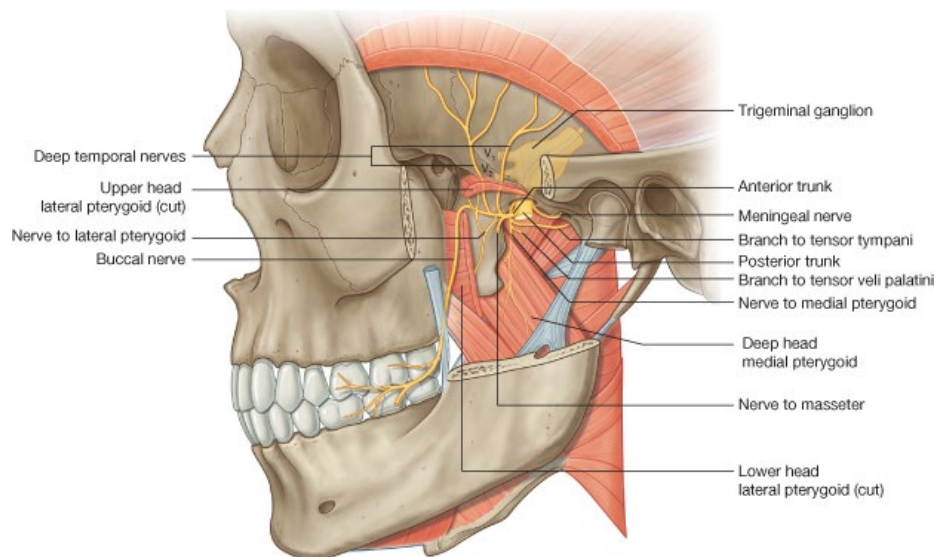
Posterior division – sensory:

- Gives rise to the:
 - **Lingual nerve**
 - **Inferior alveolar nerve**
 - **Auriculotemporal nerve**
- Lie on lateral side of medial pterygoid.
- **Lingual nerve:**
 - Tongue
- **Inferior alveolar nerve:**
 - Lower teeth, lower lip, chin
- **Auriculotemporal nerve:**
 - Temple & auricle
- **Inferior alveolar nerve:**
 - Passes into the bone of the mandible through the **mandibular foramen**
 - Passes forwards beneath the lower teeth
 - Leaves the front of the mandible through the **mental foramen**
 - Now known as the **mental nerve**, which carries sensation from lower lip and chin.
- The inferior alveolar nerve gives off a **motor** branch before it enters the mandibular foramen (this is the only motor branch of the posterior division)
- This motor nerve supplies:
 - Mylohyoid
 - Anterior belly of digastric
- **Lingual nerve:**
 - Joined by **chorda tympani** under the base of the skull (branch of facial nerve VII in the middle ear)
 - Chorda tympani leaves the petrous temporal bone of middle ear through the **petrotympanic fissure** (close to the foramen ovale).
 - Chorda tympani quickly joins the lingual nerve
 - Carries **parasympathetic fibres** from the facial nerve (VII)
 - These parasympathetic fibres synapse in the **submandibular ganglion** to supply salivary glands and mucous membrane on floor of mouth.
 - Chorda tympani also carries taste fibres in the opposite direction from the anterior 2/3 of the tongue.
- **Auriculotemporal nerve:**
 - Has **2 roots** which embrace the **middle meningeal artery**

- Passes laterally to supply sensation to:
 - Part of ear
 - Tympanic membrane
 - Temple
- Close relation to the otic ganglion at its origin

Parasympathetic innervation:

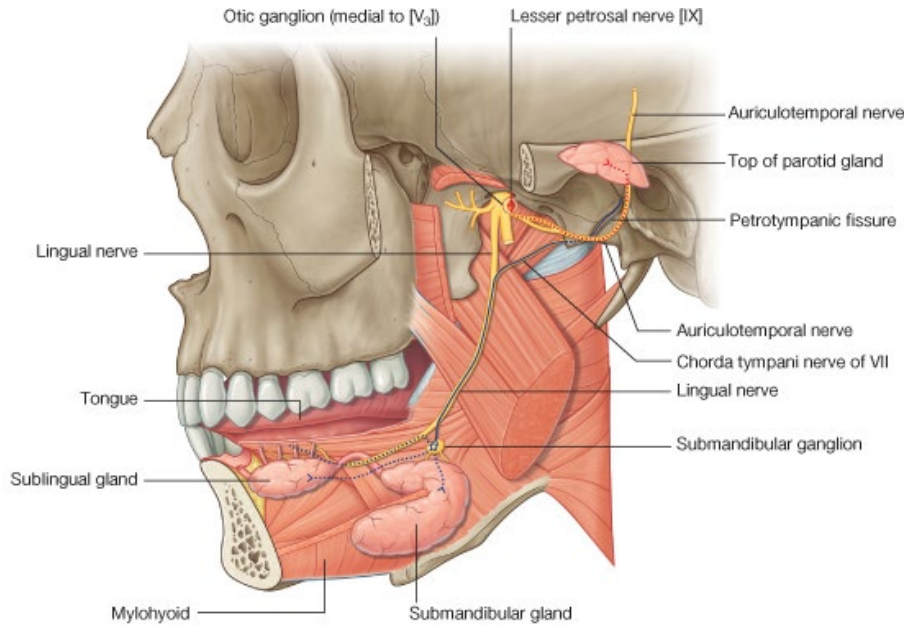
- Preganglionic parasympathetic nerves destined for the **otic ganglion** arise from the **glossopharyngeal nerve (IX)**
- Glossopharyngeal nerve passes through the **jugular foramen**
- Parasympathetic fibres leave the glossopharyngeal nerve soon after it emerges from the foramen.
- Pass up through the petrous temporal bone of the middle ear as the **lesser superficial petrosal nerve**.
- The lesser petrosal nerve then drops down through the **foramen ovale** with the mandibular division of trigeminal.
- Enters the otic ganglion, and synapses within it.
- Nerves then jump into the **auriculotemporal nerve**
- Runs in the auriculotemporal nerve to the side of the mandible where they enter the **parotid gland**
- **Sympathetic** fibres also pass to the parotid through the ganglion, but they do not synapse.



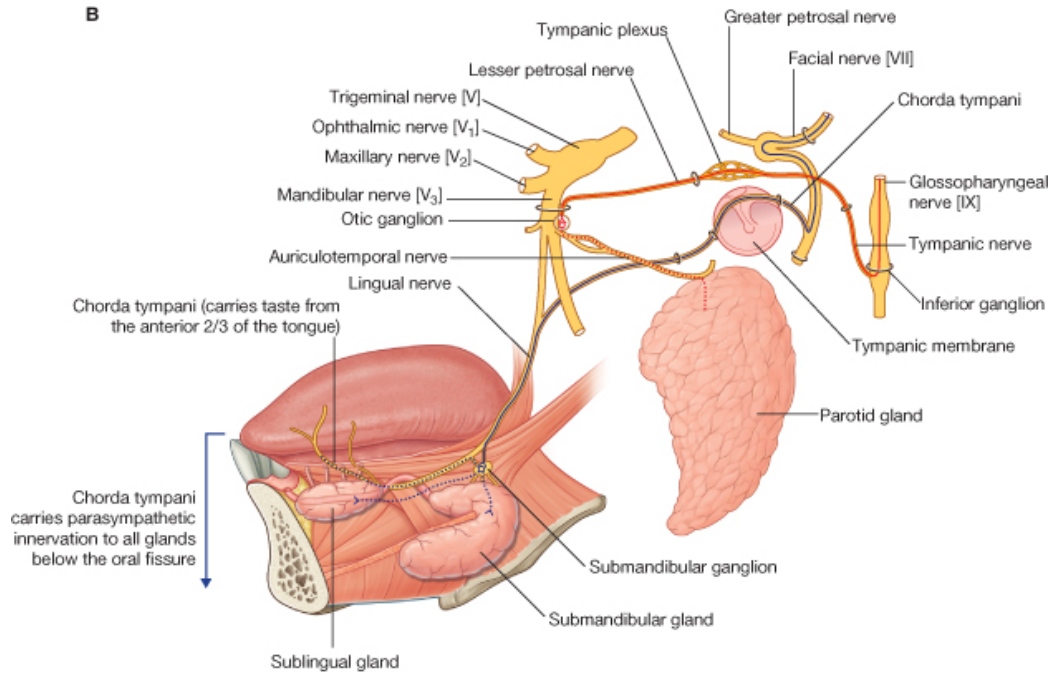
Posterior division of mandibular:

- Lingual nerve
- Inferior alveolar nerve
- Auriculotemporal nerve

A

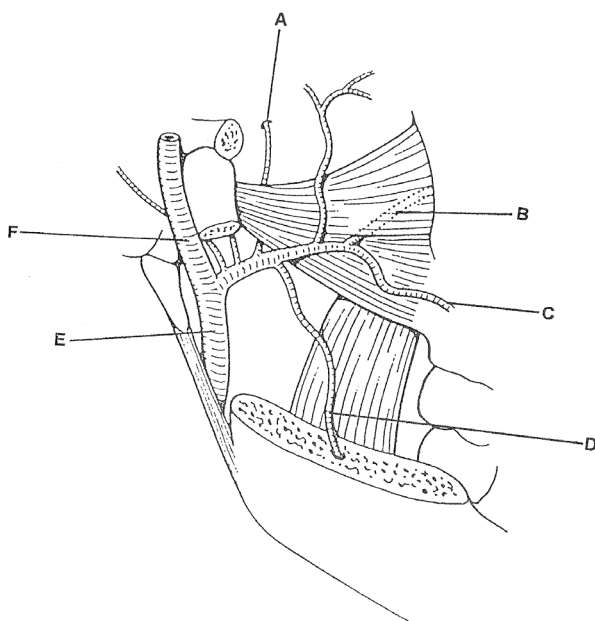


B



MAXILLARY AND SUPERFICIAL TEMPORAL ARTERIES:

- These are the 2 terminal divisions of the the external carotid at the level of the infratemporal fossa.
- **Maxillary artery** passes tortuously through the infratemporal fossa
- Passes through the 2 heads of the lateral pterygoid → pterygopalatine fossa
- The maxillary artery has several branches supplying the:
 - All the muscles of mastication
 - Ear – external acoustic meatus & tympanic membrane
 - Nose
 - Palate
 - Pharynx
- To simplify:
 - Inner 1/3 of artery supplies muscle of mastication
 - Outer 2/3 of artery supplies bone
- **Inferior alveolar artery** accompanies nerve of same name
- Emerges through mental foramen as the **mental artery**
- Supplies pulp of teeth and body mandible.
- **Middle meningeal artery** is a nutrient artery to the bones of the skull
- The artery ascends through the foramen spinosum
- Its ascent is embraced by the 2 roots of auriculotemporal nerve
- Its position is extradural (between dura and periosteum).
- **Accessory meningeal artery** ascends through the foramen ovale (with V3) to supply ganglion of trigeminal nerve.
- In the pterygopalatine fossa branches of the maxillary artery supply all the branches of the pterygopalatine ganglion
- One branch passes through the **infraorbital foramen** onto cheek (with the infraorbital nerve).



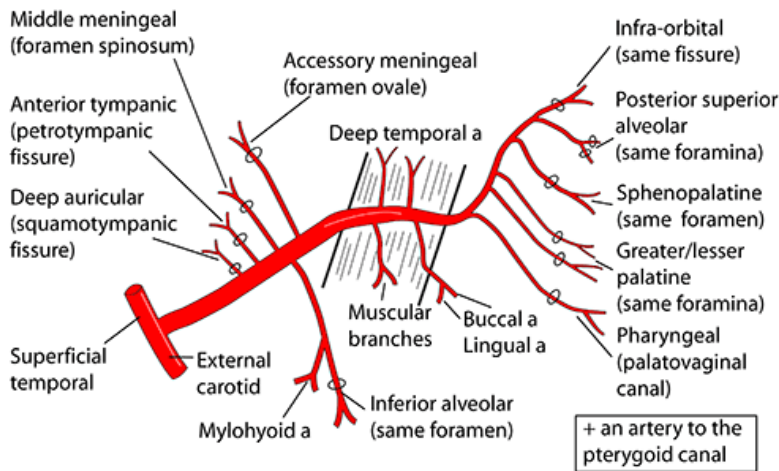
The maxillary and superficial temporal arteries are terminal branches of the external carotid artery in the infratemporal fossa. The first few branches of the maxillary artery enter bony structures associated with the infratemporal fossa.

- A Middle meningeal artery
- B Maxillary artery
- C Superior alveolar artery

- D Inferior alveolar artery
- E External carotid artery
- F Superficial temporal artery

MAXILLARY ARTERY

In infratemporal fossa, either within or lateral to the superficial head of lateral pterygoid muscle. This muscle is shown below



**BEFORE LATERAL
PTERYGOID
5 BRANCHES
INTO BONE**

**LATERAL OR
WITHIN LATERAL
PTERYGOID. 4/5
BRANCHES TO
SOFT TISSUE**

**BEYOND
LATERAL
PTERYGOID
5/6 BRANCHES
WITH NERVES**

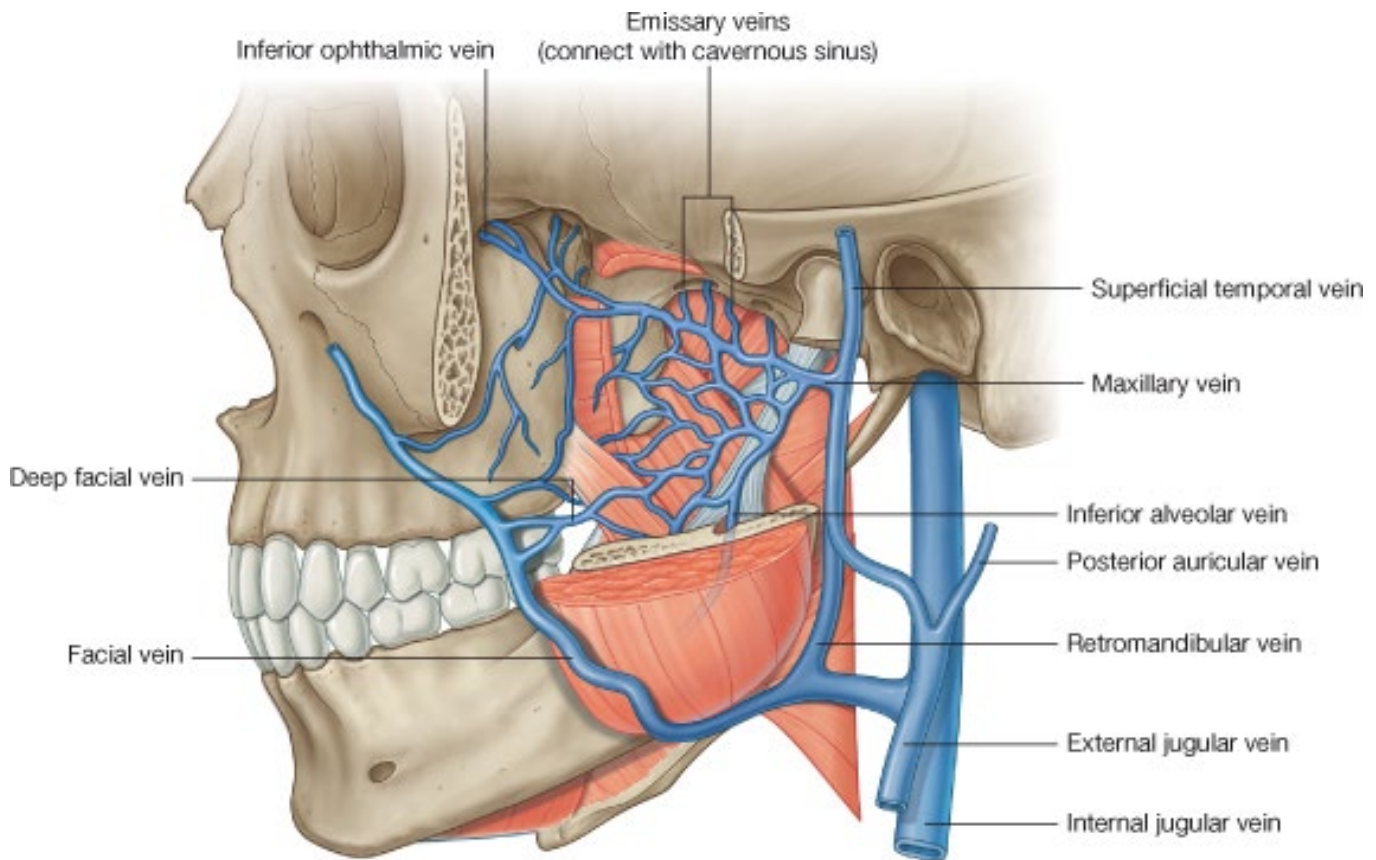
PTERYGOID PLEXUS OF VEINS:

- Network of veins lying around the pterygoid muscles – **pterygoid plexus of veins**
- Receives blood from veins accompanying local arteries
- Also receives blood from **inferior orbital veins** through the inferior orbital fissure
- Eventually the plexus drains into a pair of **short maxillary veins** which lie deep to the neck of the mandible.
- These join the **superficial temporal vein** to form the **retromandibular vein**
- **Deep facial vein** connects the plexus with the facial vein.
- **Retromandibular + facial → drain into IJV**
- **Retromandibular also drains into EJV**
- Yawning squeezes blood out of the pterygoid plexus.
- The pterygoid venous plexus also drains through the foramen ovale into the **cavernous sinus**
- This is a common path for infection of the face to track back to the cavernous sinus.
- Misplaced local anaesthetic in the mouth can enter the pterygoid venous plexus and drain into the cavernous sinus.
- → Transient anaesthesia of **abducens nerve (VI)** which runs free in the cavernous sinus (the other cranial nerves in the sinus run in the dura of its walls).
- Abducens nerve supplies the lateral rectus muscle of eye Δ get double vision if local anaesthetic reaches the cavernous sinus.

Pterygoid plexus of veins:

- **Infratemporal fossa + pterygopalatine fossa**
- **Inferior orbital**
- **Facial**

- **Cavernosus sinus**



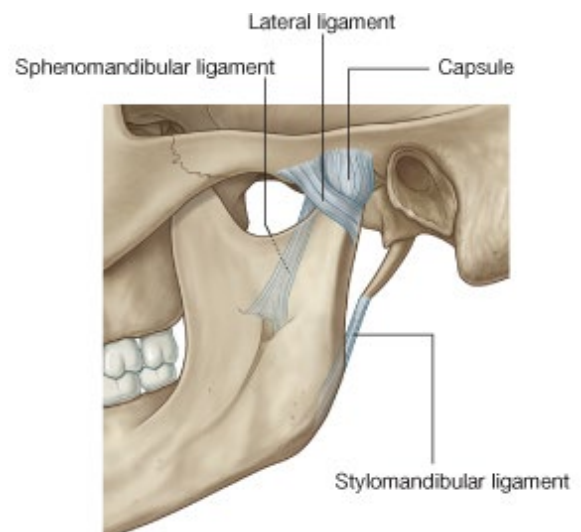
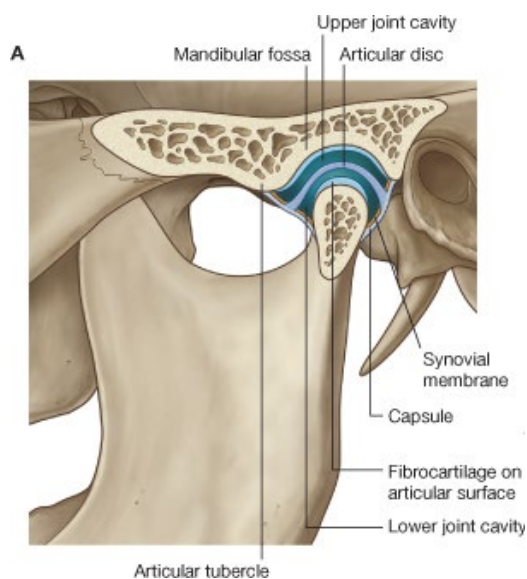
TEMPOROMANDIBULAR JOINT:

- **Temporomandibular joint (TMJ)**
- Synovial joint between:
 - **Glenoid fossa** of undersurface of temporal bone
 - **Condyle**/head of the mandible
- The articular surfaces do not have a complete covering of hyaline cartilage.
- Fibrous capsule attached to articular margins, lined with synovial membrane
- Lateral part of capsule is thickened as the **lateral ligament**
- Joint cavity is completely divided into 2 by disc of fibrous CT
- Disc = **meniscus**
- Upper joint cavity is large and includes:
 - Concave surface of temporal bone
 - Convex bulge on undersurface of root of zygomatic arch – **articular eminence**
- Large upper cavity allows sliding of the head of the mandible forwards onto the articular eminence – during wide opening of the mouth.
- Lower cavity is simpler and allows hinge movements of jaw (although sliding movements are also likely on opening of jaw).

- Capsule of TMJ is lax enough to allow some side-to-side movement.

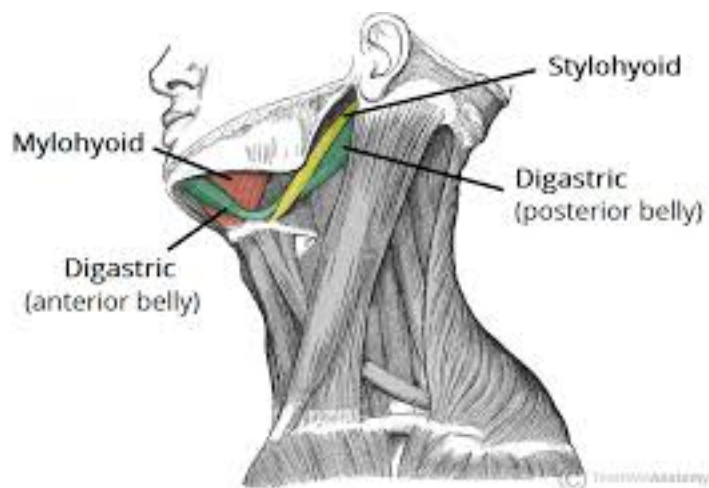
Ligaments of the TMJ:

- **Lateral ligament**
- **Sphenomandibular ligament:**
 - Arises from **spine** of sphenoid (on base of skull)
 - Inserts into **lingula** – spur of bone that flanks the mandibular foramen.
 - (ligament is a remnant of the perichondrium of **Meckel's cartilage**)
- **Stylomandibular ligament:**
 - Arises from styloid process
 - Attaches to the angle of the mandible
 - (Condensation of deep investing cervical fascia)



- Opening the mouth:
 - Condyle and articular disc move downwards and forwards onto articular eminence
 - Head of condyle rotates on lower surface of disc.
- Protrusion of the jaw:
 - Mandibular heads move anterior
 - Due to action of lateral pterygoid muscles.
- When **chewing** food, tend to chew on one side then switch the bolus to the other side for a while.
- This concentrates all the muscles force from both sides of the skull between the teeth of the chewing side.
- When chewing on one side:
 - Head of mandible on opposite site slips onto the articular eminence
 - Head of mandible on the chewing side remains against the back of the eminence.
- Δ when a patient fractures their condylar neck, it is more painful to chew on the *opposite* side to the fracture.
- Closure of mouth and occlusion of teeth is carried out by:

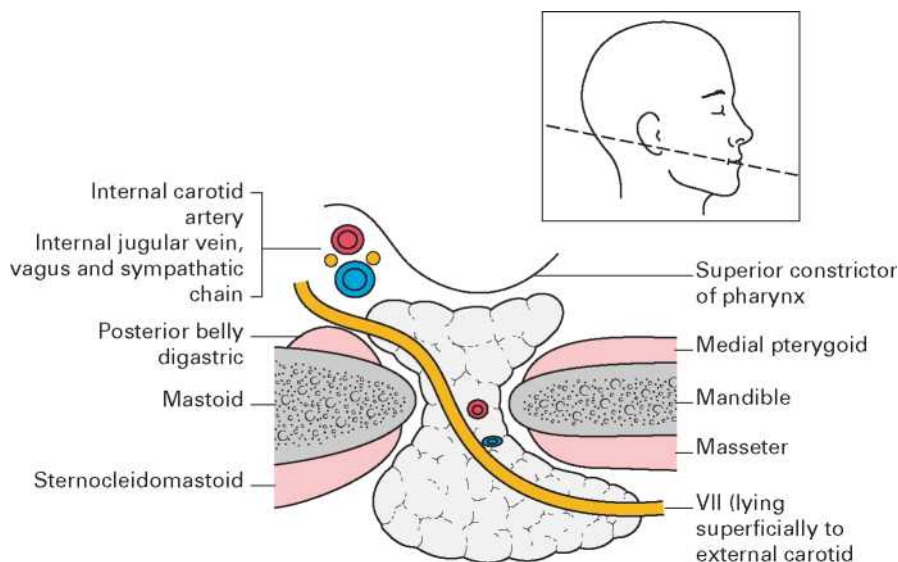
- Temporalis
 - Masseter
 - Medial pterygoid muscle
- Upper head of lateral pterygoid is also active during jaw closure, as it stabilises the meniscus.
 - Opening the mouth against resistance is effected by:
 - Lower head of lateral pterygoid
 - **Digastric muscle**



PAROTID GLAND

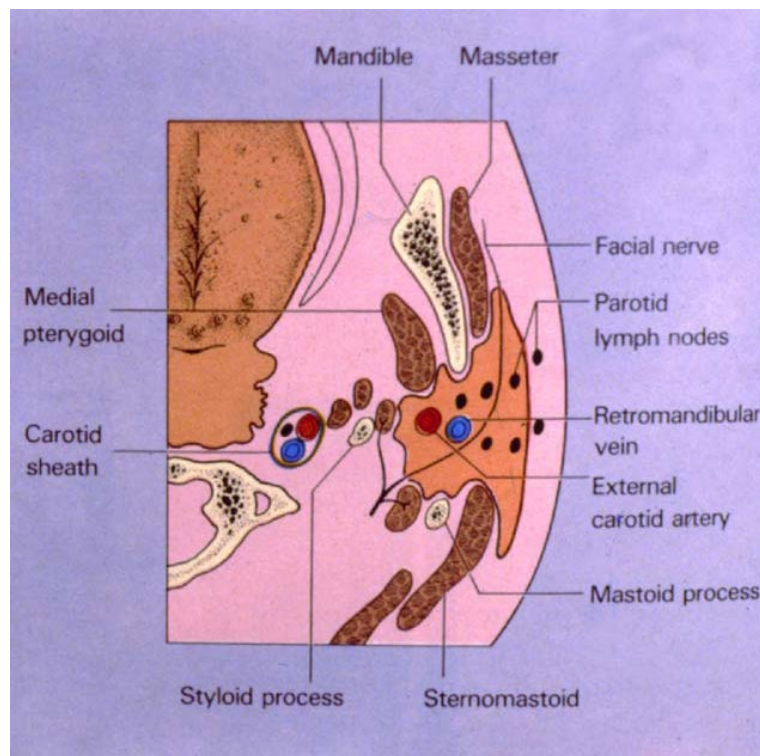
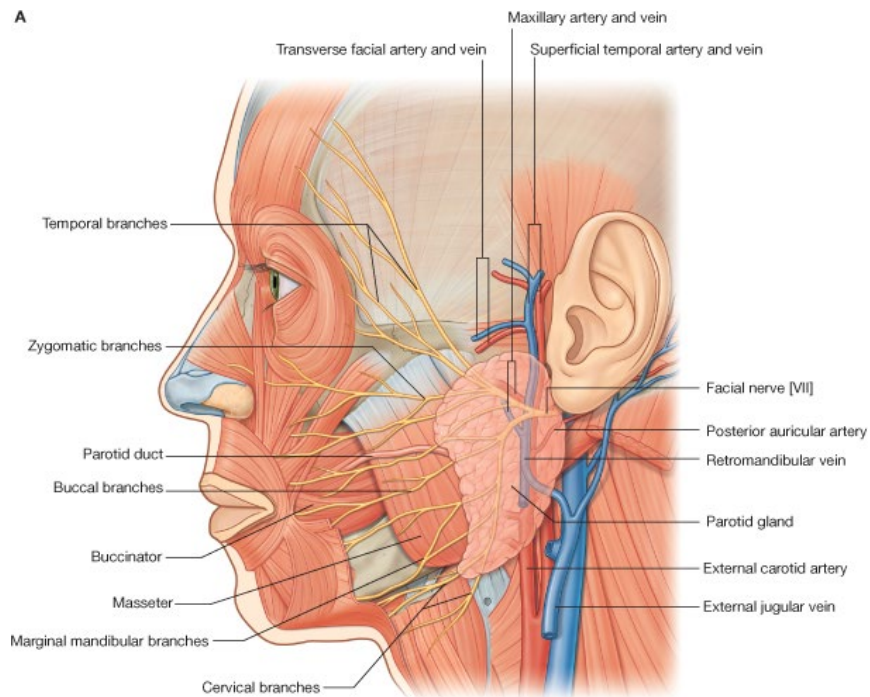
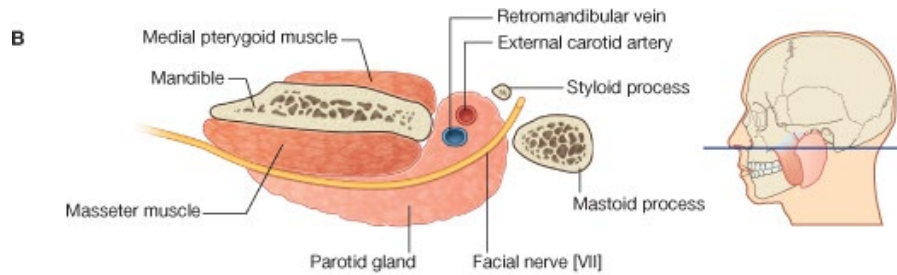
- **Serous salivary gland**
- There is no mucous-secreting acini in the parotid
- Parotid gland squeezes into the space available around the ramus of the mandible.
 - Part lying on the surface is called the **superficial lobe**
 - The deep tapering edge is called the **deep lobe**
- Behind it extends up to the neck of the mandible – the **glenoid lobe**
- It is surrounded by deep **investing fascia** of the neck
- Because it is completely enveloped by investing fascia, swelling of the parotid → considerable tension and pain.
- Reason why mumps (viral parotitis) is so painful.
- **Superficial lobe** extends onto the surface of the masseter muscle
- **Parotid duct** emerges from its convex anterior edge
- Parotid duct pierces the cheek at level of 2nd upper molar tooth at the level of its neck/cervix
- If the duct opened any lower in the cheek, it would be prone to being chewed during eating.

- Branches of the **facial nerve** are embedded in the parotid – these leave the anterior border to supply the superficial muscles of the face.
- The **glenoid lobe**:
 - Lies behind the temporomandibular joint
 - In contact with the bony part of the external acoustic meatus.
 - Close to the auriculotemporal branch of the mandibular nerve
- Posteriorly the gland is related to the:
 - **Mastoid process**
 - **Sternocleidomastoid**
- The **deep lobe** is related to the:
 - Styloid process (and its muscles)
 - Internal carotid artery & internal jugular vein (within the carotid sheath)



- Structures passing through the substance of the gland include:
 - **External carotid artery**
 - **Retromandibular vein**
 - **Facial nerve (VII)**
- This makes removal of cysts / tumours from the parotid very difficult – must not damage the facial nerve during surgery.
- Within the gland the order of these 3 structures is, from superficial to deep:
 - **Facial nerve (VII)** → **retromandibular vein** → **external carotid artery**
Fires *Rarely* *Extinguish*
- Remember that the auriculotemporal branch is the final part of the pathway for parasympathetic fibres to reach the parotid gland.
- These parasympathetic fibres have originated from the **glossopharyngeal nerve (IX)** → lesser superficial petrosal nerve → foramen ovale → synapse in otic ganglion → auriculotemporal nerve (flanking the MMA)
- Parasympathetic stimulates secretion of saliva.
- Sympathetic fibres also innervate the parotid gland.

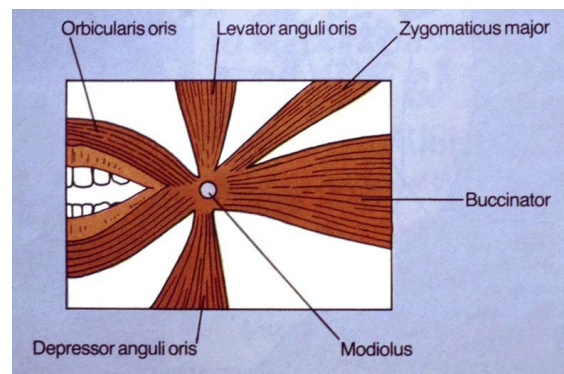
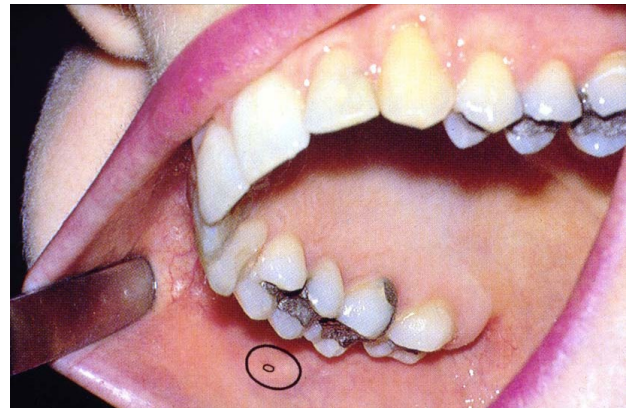
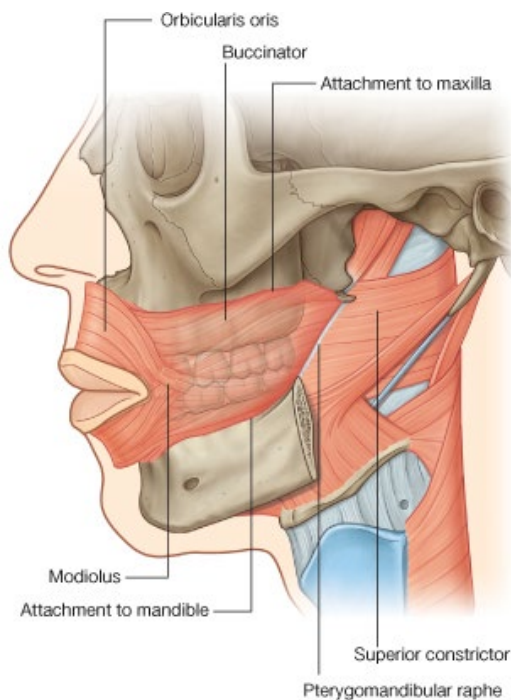
- Parasympathetic and sympathetic fibres are responsible for changing:
 - Composition of saliva
 - Volume of salivary flow (sympathetic vasoconstriction changes blood flow).



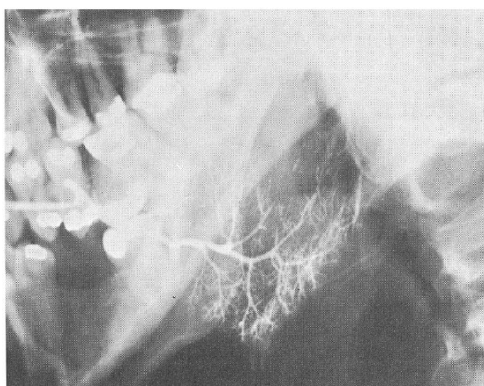
- **Frey's syndrome:** when the parotid is surgically removed, the autonomic fibres which normally supply it grow into the skin. Δ a stimulus to salivation will cause flushing and sweating of the face.

BUCCINATOR MUSCLE

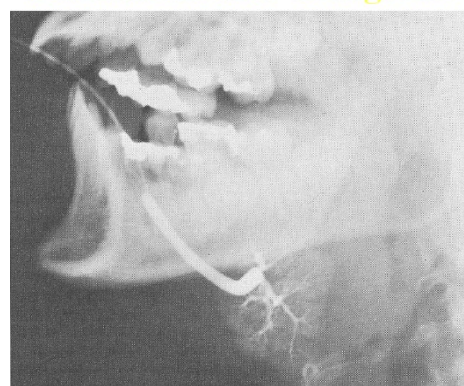
- A muscle of facial expression supplied by the **facial nerve (VII)**
- It arises from the **pterygomandibular raphe** (opposite side to superior constrictor muscle)
- Superior constrictor muscle also originates from this raphe – posterior to the buccinator.
- Runs forwards to the angle of the mouth
- Attached above and below the molar and premolar teeth to the maxilla and mandible.
- Its upper and lower fibres cross (decussate) as they reach the corner of the mouth
- This is the point at which many of the muscles of facial expression mingle, and its called the **modiolus**.
- The buccinator fibres are continuous with the orbicularis oris at the modiolus.
- Important function of the buccinator is to squeeze food from the cheek back between the teeth and into the mouth again for more chewing before being swallowed.
- Also controls, to some extent, the flow of saliva through the parotid duct & prevents food and debris being squeezed back into the duct.
- Does this by contracting around the duct as the duct enters the mouth – the buccinator fibres decussate around the parotid duct.



Parotid sialogram



Submandibular sialogram



- **Sialogram:** radioactive substance is injected into the salivary ducts to reveal the salivary glands.