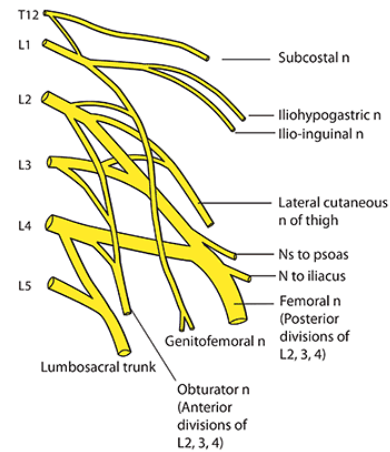
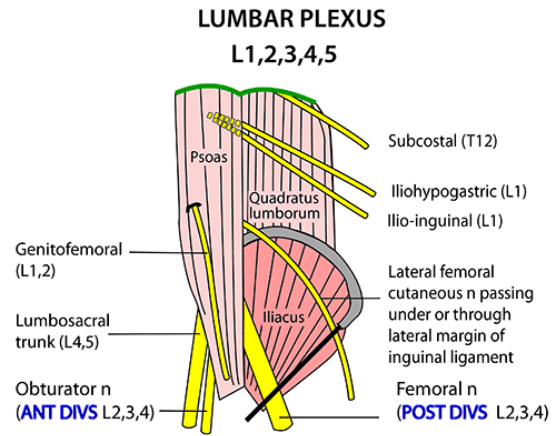


NERVES AROUND HIP:

LUMBAR PLEXUS: L1,2,3,4,5

- Anterior L2,3,4 = **OBTURATOR NERVE**
- Posterior L2,3,4 = **FEMORAL NERVE**
- Iliohypogastric (L1)
- Ilioinguinal (L1)
- Lateral femoral cutaneous nerve
- Genitofemoral (L1,2)
- Lumbosacral trunk (L4,5)



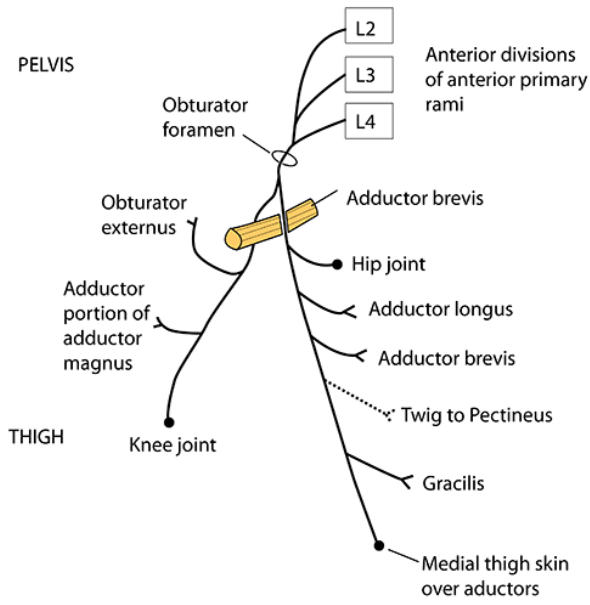
OBTURATOR NERVE: L2,3,4 ant div

- Anterior + posterior divisions split around adductor brevis
- Supply adductors of hip (except pectineus)
- Skin over medial thigh

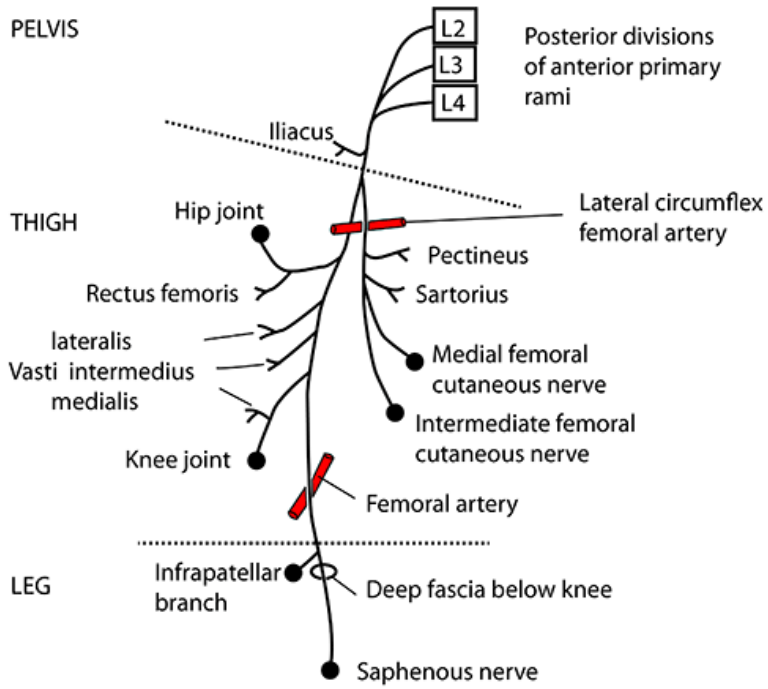
FEMORAL NERVE: L2,3,4 post div

- Iliopsoas
- Quadriceps femoris
- Pectineus (adductor)
- Sartorius
- Medial + intermediate femoral cutaneous nerves
- Goes on to form saphenous nerve

OBTURATOR NERVE

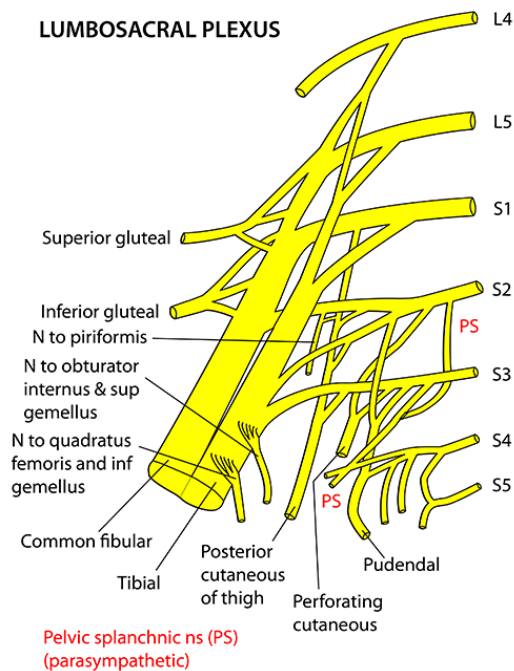


FEMORAL NERVE



LUMBOSACRAL PLEXUS: L4,5 + S1,2,3,4,5

- 6 branches (6Ps)
 - 3 leave GSF: post fem cut, perforating cut, pudendal
 - 3 stay in pelvis: piriformis, perineal, pelvic splanchnic PS
- Anterior division
 - Lateral rotator muscles
 - Nerve to quadrator femoris
 - Nerve to obturator internus
 - Tibial division of sciatic nerve
- Posterior division
 - Superior + inferior gluteal nerves
 - Common fibular division of sciatic nerve



SACRAL PLEXUS L4,5,S1,2,3,4,5

Lies on piriformis on posterior wall of pelvis, deep to the vessels & covered by parietal pelvic fascia

6 BRANCHES OFF THE SACRAL ROOTS BEFORE THEY DIVIDE INTO ANTERIOR & POSTERIOR DIVISIONS They all begin with the letter "P"

1. Posterior femoral cutaneous nerve (S1,2,3)
2. Pudendal nerve (S2,3,4)
 - (1 & 2 - leave via greater sciatic foramen)
3. Perforating cutaneous nerve (S2,3)
 - (3 - perforates sacrotuberous ligament)
4. Nerve to piriformis (S1,2)
5. Perineal branch of S4 (to levator ani)
6. Pelvic splanchnics (S2,3,4)
 - Parasympathetic motor to bladder, hind gut, erection.
 - Sensory for distension & pain of bladder, lower uterus, lower colon & rectum
 - (4,5,6 - all remain in pelvis)

FROM ANTERIOR DIVISIONS

- Nerve to quadratus femoris (L4,5,S1)
- Nerve to obturator internus (L5,S1,2)
- Tibial portion of sciatic nerve (L4,5,S1,2,3) (see sciatic nerve in leg section)

FROM POSTERIOR DIVISIONS

- Superior gluteal (L4,5,S1)
- Inferior gluteal (L5,S1,2)
- Common fibular portion of sciatic nerve (L4,5,S1,2) (see sciatic nerve in leg section)

NOTES ON SACRAL PLEXUS AND SCIATIC NERVE

There are six nerves that arise from the roots
of the sacral plexus that have the letter "P"

Piriformis, nerve to:	S1,2	Remains in pelvis to supply this muscle
Posterior femoral cutaneous nerve:	S1,2,3	Leaves pelvis via greater sciatic foramen
Perforating cutaneous nerve:	S2,3	Leaves pelvis via greater sciatic foramen
Pudendal nerve:	S2,3,4	Leaves pelvis via greater sciatic foramen
Pelvic splanchnic (parasympathetic) nerves:	S2,3,4	Remains in pelvis to supply pelvic organs
Perineal branch of S4:	S4	Remains in pelvis to supply levator ani

3 nerves remain in the pelvis & 3 exit via the greater sciatic foramen

SCIATIC NERVE

Anterior division

Tibial to flexors (L4,5,S1,2,3)
Nerve to obturator internus (L5,S1,2)
Nerve to quadratus femoris (L4,5,S1)

Posterior division

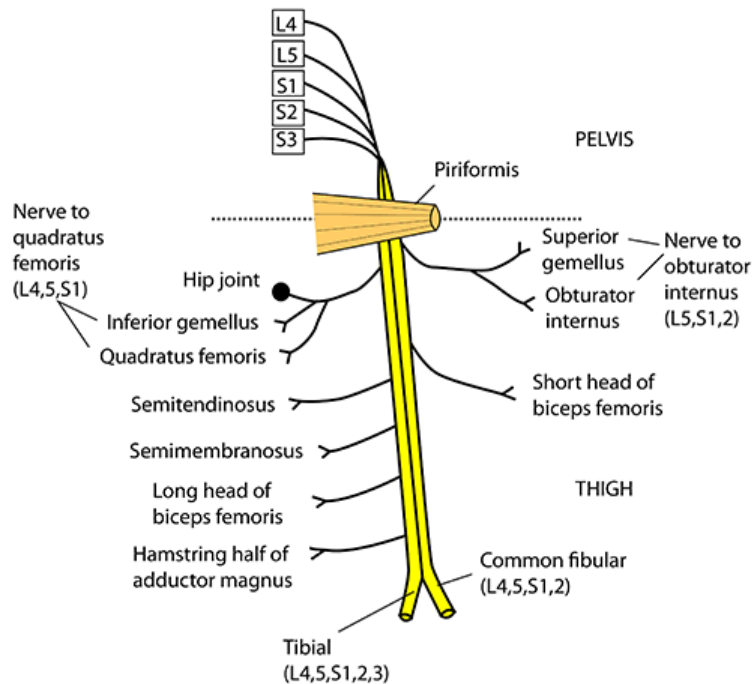
Common fibular to extensors
Superior gluteal (L4,5,S1)
Inferior gluteal (L5,S1,2)

SCIATIC NERVE: L4,5 + S1,2,3

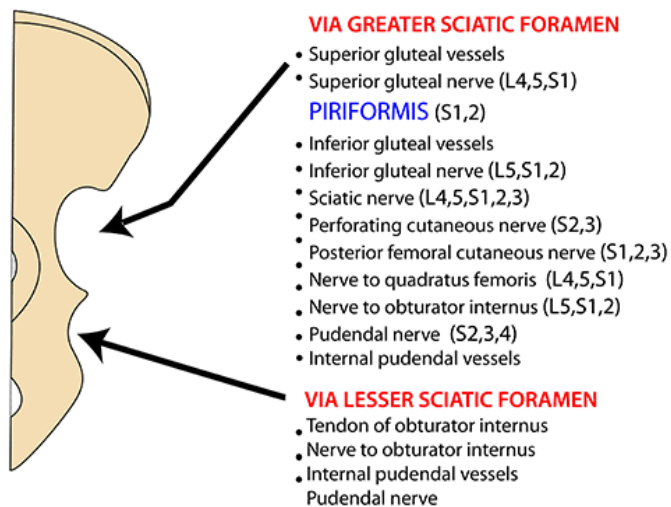
Arises from lumbosacral plexus

- Posterior compartment of thigh (knee flexors):
 - Biceps femoris
 - Semitendinosus
 - Semimembranosus
 - Lowermost part of adductor magnus
- Most of it is tibial branch
- Common fibular part does:
 - Short head of biceps femoris

RIGHT SCIATIC NERVE VIEWED FROM BEHIND



SCIATIC FORAMINA STRUCTURES ENTERING & LEAVING



Obturator internus stuff goes through lesser sciatic foramen (+ pudendal stuff which has just left the greater sciatic foramen)